

Ethambutol-induced optic neuropathy

Martin Kyncl, Martin Fus, Jan Lestak

Purpose. A case report of a 40-year-old patient with tuberculosis treated with ethambutol is described. Within six months of starting treatment, there was a painless sudden decline in visual function. Despite the known complications of ethambutol treatment, it was discontinued after another three months.

Methods. In the case report, we highlight the damage to the dominantly peripheral visual pathways. Using electrophysiological examinations, we showed a significant alteration in the optic nerves. Optical Coherence Tomography (OCT) showed progressive loss of vessel density and nerve fibre layer of retinal ganglion cells. Perimetric examination showed both a central decrease in sensitivity and mainly scotomas in the temporal parts of the visual fields. Although there was improvement in visual fields over time, OCT findings indicated progression of ethambutol-induced optic neuropathy (EON). Magnetic Resonance Imaging confirmed the alteration in the peripheral part of the visual pathway (intraorbital, intracranial parts of optic nerves, chiasma, and optic tracts).

Conclusion. Even though EON is not an unknown complication, new cases still occur and, unfortunately, with an irreversible course. Therefore, it is important to draw attention constantly to this complication and to consider it not only in ophthalmologists' surgeries.

Key words: ethambutol, optic neuropathy, vessel density, magnetic resonance imaging

Received: March 10, 2022; Revised: March 10, 2022; Accepted: April 29, 2022; Available online: May 16, 2022

<https://doi.org/10.5507/bp.2022.022>

© 2022 The Authors; <https://creativecommons.org/licenses/by/4.0/>

Faculty of Biomedical Engineering, Czech Technical University in Prague, 272 01 Kladno

Corresponding author: Jan Lestak, e-mail: lestak@seznam.cz

INTRODUCTION

Ethambutol hydrochloride, despite having many side effects, is still the first choice medicine in the treatment of tuberculosis¹. Ethambutol-induced optic neuropathy (EON) is a known dose-dependent complication of ethambutol use². Toxicity is usually reversible after discontinuation of the medicine. However, there are also reports of permanent visual impairment^{3,4}. The clinical findings of EON are characterised by a painless decrease in visual acuity and centrocecal scotomas in the visual fields⁵. Czech ophthalmological literature also contains case reports on this topic⁶⁻⁹. In 2019, a total of 464 cases of tuberculosis of all forms and locations were reported in the Czech Republic, i.e. 4.3 cases per 100 000 inhabitants. Of these, 141 (30.4%) were foreigners. Compared to 2018, the number increased by 20 cases¹⁰.

CASE REPORT

The study was performed according to the Declaration of Helsinki and was approved by the internal ethics committee of the Ophthalmology Clinic JL (Prague, Czech Republic). All details, medical records, figures, medical history or test results were used with the written consent for publication from the patient, which is available from the corresponding author on reasonable request. All data used were anonymized.

A female (age 40 years) weighing 65 kg was diagnosed with mycobacteriosis of the lungs, caused by *Mycobacterium avium* in 5/2020. On 6 June 2020, rifampicin 600 mg/day, ethambutol 1.4 g/day, and klarithromycin 500 mg/day were administered. In 12/2020, the patient experienced a sudden decrease in vision, not accompanied by pain behind the eyes or in the head. In addition to a decrease in vision, she also had photophobia. She was examined by the regional ophthalmologist. Subsequently at the Ophthalmological Clinic of the University Hospital, suspected optic neuritis was diagnosed, verified by Magnetic Resonance Imaging. She was taking ethambutol until 3/2021. She was seen in our department in 3/2021. We found attenuated pupillary responses. Ocular findings were normal, except for temporal atrophy of both optic discs. The patient had an achromatopsia. Visual acuity (in decimal values) was 0.08 without correction in both eyes. The intraocular pressure (IOP) was 19 mm Hg in both eyes.

Perimetric examination showed relative central scotomas, transitioning to absolute loss of sensitivity in the temporal halves of the visual fields. The examination was performed using the Medmont M700 rapid threshold program in the range of 0-30 degrees (Medmont Pty Ltd, Australia). See Fig. 2.

Electroretinographic examination (pattern electroretinograph-PERG) showed normal retinal findings in both eyes. Visual evoked potential (PVEP) showed significant decrease in A1 and A2 amplitudes and prolongation of

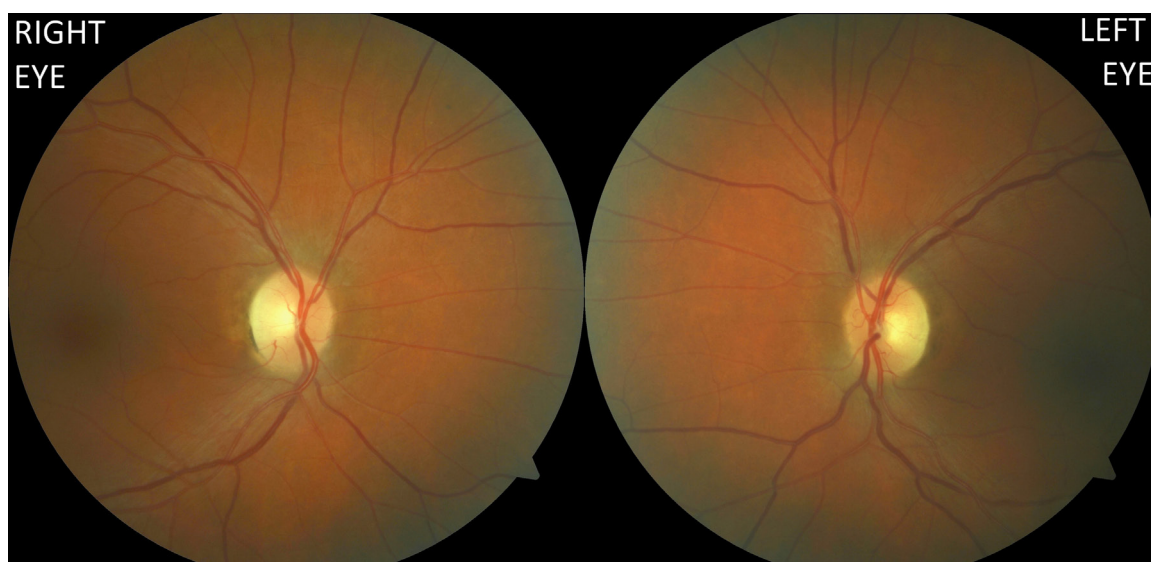


Fig. 1. Bitemporal fading of both optic discs.




Fig. 2. Visual field of the right and left eye.

P100 oscillation to 129 ms. When smaller squares were used, the responses were almost non-exclusive. The examination was performed with the Roland Consult - electrophysiological diagnostic system (Germany) according to the ISCEV methodology.

The nerve fibre layer (RNFL) was 127 μm on the right and 126 on the left. Small Vessel Density in the radial peripapillary capillary area (RPC) on the right was 47%, on the left 51.5%. The examination was performed using the Avanti RTVue XR from Optovue (results in Fig. 3).

Magnetic Resonance Imaging (MRI) was performed in our department on 19 March 2021. The follow-up MRI scan was performed on 25 June 2021 with intravenous injection of gadolinium contrast agent. Imaging was performed in both cases with the Achieva dStream TX SERIES 3T device (Philips HealthCare, Best, Nederland), using a 32-channel SENSE RF head coil. The imaging protocol included T2 mDIXON coronal and axial sequences (TR/TE 3000/80 ms), 3D FLAIR (TR/TE 4800/269ms), T2 3D DRIVE (TR/TE 2000/240 ms), Turbo Fiel Echo (TFE) T1 3D sequence (TR/TE 7/3 ms), VenBold (TR/TE 15/21) and DWI (TR/TE 3616/79 ms). During the

follow-up MRI, the protocol was repeated and, in addition, TFE T1 3D (TR/TE 7/3 ms) post-contrast sequences were added with 10ml of gadolinium contrast agent administered intravenously, without complication. The first MRI scan showed a signal change in the intraorbital parts of the optic nerves, in the chiasma and in the retrochiasmatic part of the optic pathway. The changes were hypersignal in T2 and FLAIR images, hyposignal in T1, expressed mainly centrally in nerve structures, and the optic nerve chiasm showed slight enlargement. Another finding on brain MRI imaging was numerous small foci of hyperintensities in T2 and FLAIR images in the white matter of both cerebral hemispheres, probably of post-inflammatory or older vascular aetiology. See Fig. 4.

We concluded the finding as optic neuropathy following EB treatment. The patient was treated with vitamin therapy with lutein (Occuvite lutein). At the last examination in June 2021, there was evidence of optic disc atrophy on the fundus, see Fig. 5. Visual acuity was 0.16 (in decimal values) without correction. Achromatopsy persists. IOP 18/16 mmHg. The finding in the visual field was improved (Fig. 6). RNFL dropped to 95 and 96, respec-

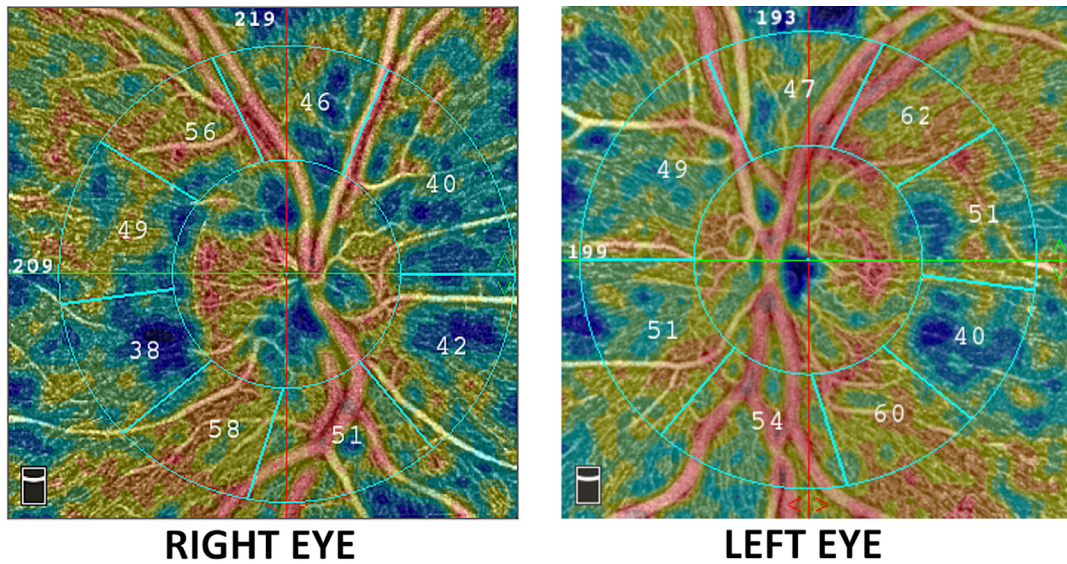


Fig. 3. Vessel Density in the radial peripapillary capillary area (RPC).

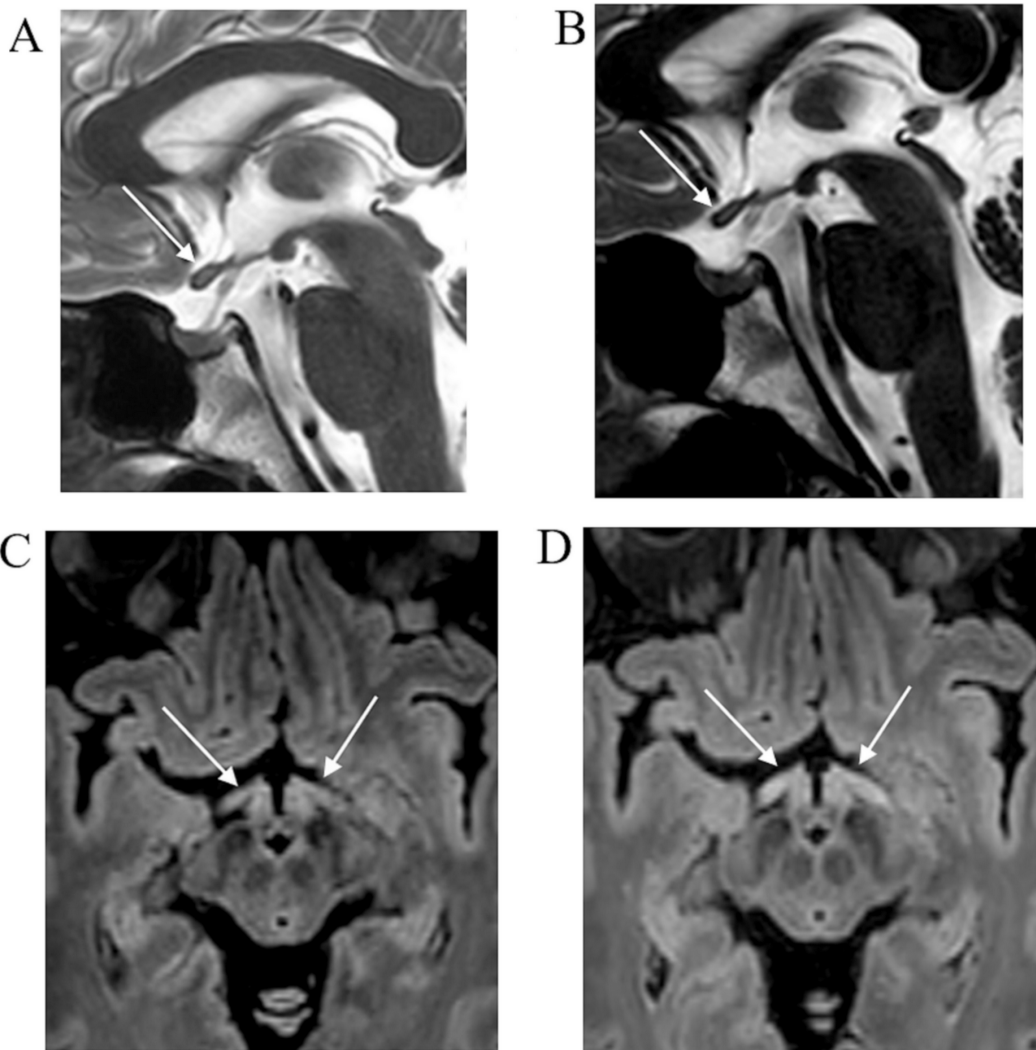


Fig. 4. Series of MRI brain scans in March 2021 (A, C) and control in June 2021 (B, D). Sagittal T2 sequence (A) shows signal change centrally in the chiasma (arrows); in the check-up examination (B) signal change persists, chiasma atrophy occurs. FLAIR (C, D) shows the evolution of signal changes over time (arrows), with the progression of changes on the MRI follow-up scan in June (D).

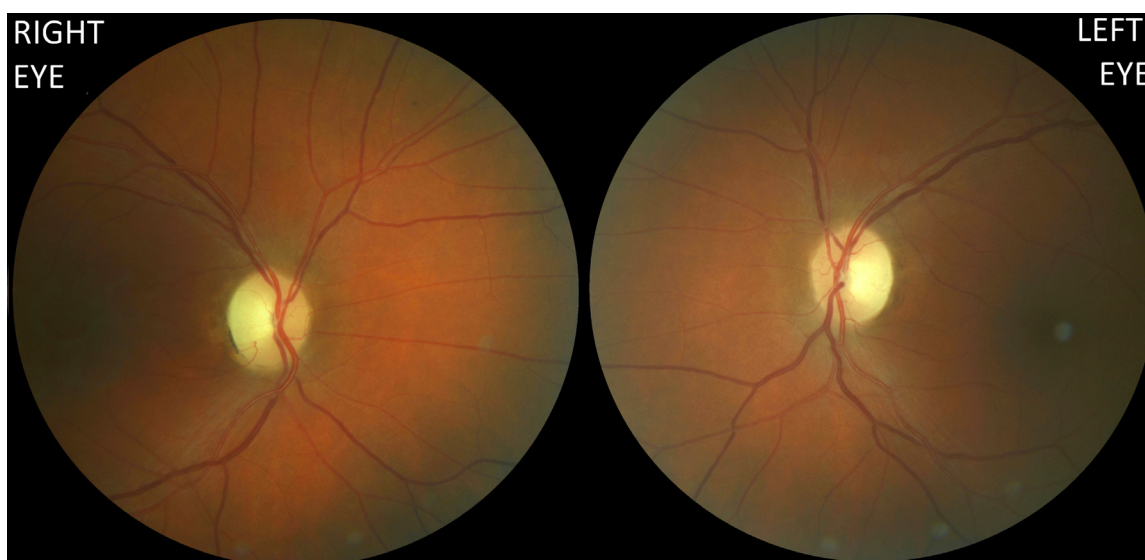


Fig. 5. Progression of atrophy of the optic discs. Visual acuity (in decimal values) was 0.16 without correction in both eyes. RNFL dropped to 95 μm in the right eye and 96 μm in the left eye. Similarly, RPC Vessel Density decreased to 43.5% in the right eye and 47.5% in the left eye.

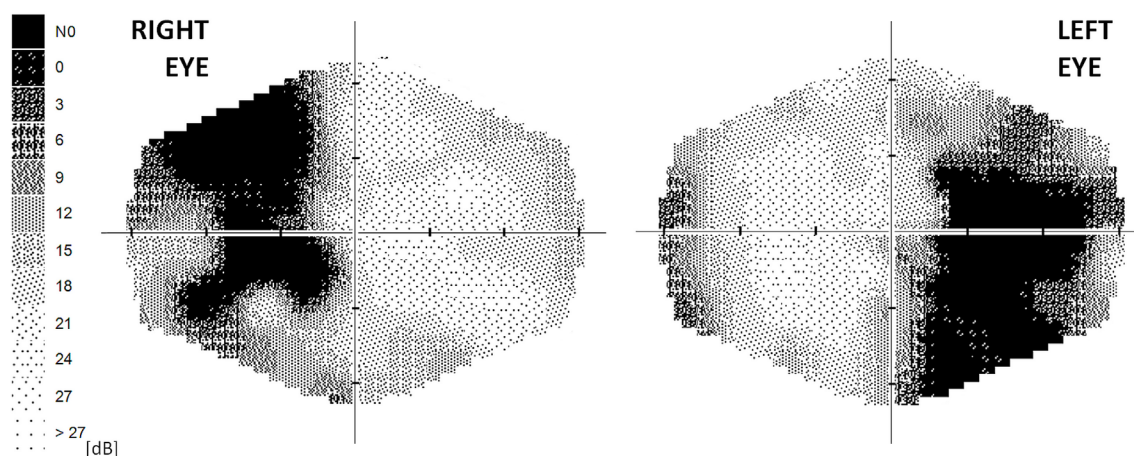


Fig. 6. Field of vision three months following discontinuation of ethambutol.

tively. Similarly, RPC Vessel Density (%) at 43.5 and 47.5 respectively (Fig. 7).

Follow-up MRI scan on 25 June 2021 showed progression of the signal changes observed during the first scan. The signal change of the chiasma persisted, but its slight atrophy had already occurred. Signal regression was evident in the intraorbital parts of both optic nerves. In contrast, in the retrochiasmatic optical pathways, the signal change was more pronounced, only with a small extension of the structures. The deposits in the white matter of the cerebral hemispheres did not change in number or character; no new deposits appeared. None of the brain changes showed opacification after intravenous administration of contrast agent.

DISCUSSION

According to the SmPC of ethambutol hydrochloride, the recommended dosage is 15 mg/kg/day for primoinfection. For already treated patients, 25 mg/kg for 60 days is recommended. Then a maintenance dose of 15 mg/kg of the patient's weight. Our patient took 21.5 mg/kg/day for nine months. After six months, visual impairment occurred.

The incidence of EON depends not only on the dose, but also on the duration of usage. Studies have shown an incidence of EON in 18% at a dose of 35 mg/kg/day, 5-6% at a dose of 25 mg/kg/day, 3% at a dose of 20 mg/kg/day and 1% at a dose of 15 mg/kg/day¹¹⁻¹³.

Krchnavá and Slámová followed 300 patients treated with ethambutol. In 11 patients, they found minor visual disturbances during treatment that did not lead to discontinuation of EB treatment. Another 9 patients had

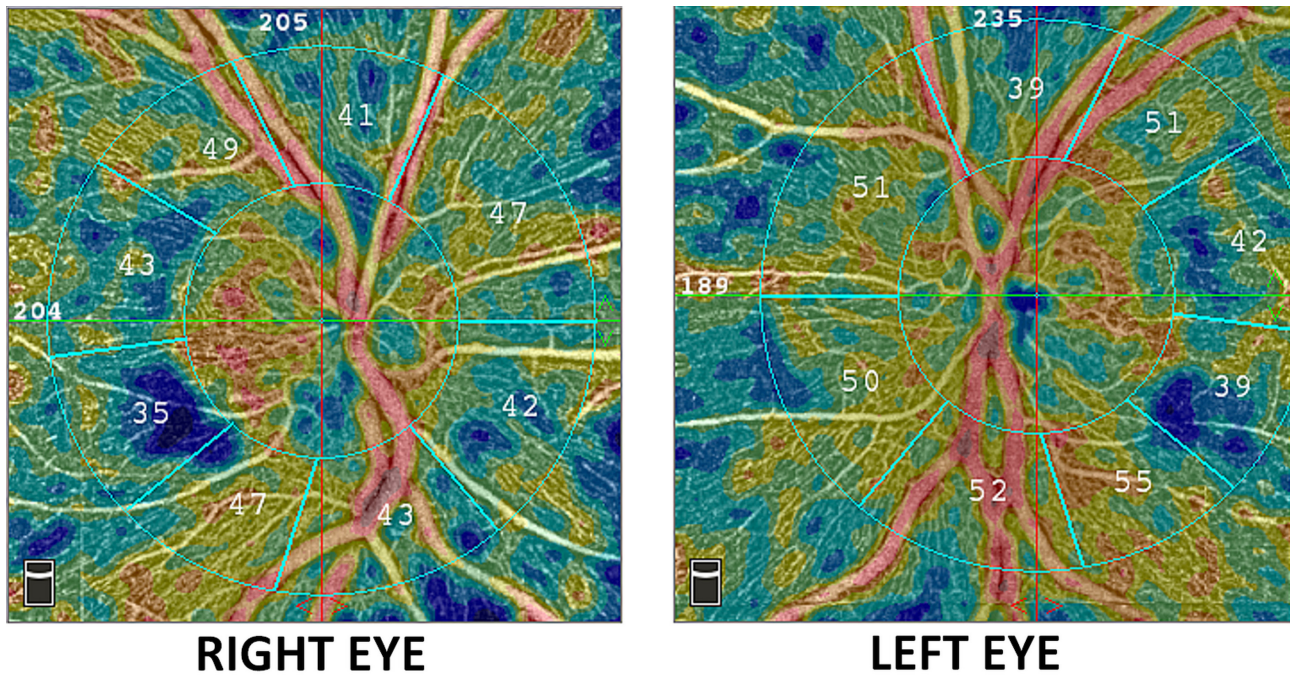


Fig. 7. Vessel Density in the RPC area three months following ethambutol discontinuation.

significant visual alterations. In these patients, EB treatment was stopped and vitamin therapy was started. All these patients showed improvement of visual function 2-4 months after discontinuation of treatment⁷.

EON is manifested by bilateral painless decrease of vision, centrocecal scotoma and impaired colour vision¹⁴.

In most patients with visual complications, but without optic nerve atrophy, visual function recovers weeks to months following immediate discontinuation of treatment¹⁵. The presence of optic disc changes indicates a poor prognosis for EON (ref.¹⁴).

EON that was induced in a monkey experiment demonstrated selective damage to the chiasm^{16,17}. Lessell then histopathologically demonstrated bilateral focal axonal oedema in the chiasma and intracranial part of the optic nerves, without demyelination¹⁸. Although it is not a typical bitemporal haemianopia, which should respect the central vertical meridian, many authors have described it for EON (ref.¹⁹⁻²³). Heng et al. demonstrated retinal ganglion cell damage in a rat model²⁴. We did not find any retinal alteration, but severe visual pathway abnormality (PVEP) by pattern electroretinogram (PERG) in our patient. A similar prolongation of P100 latency was also observed by Kim and Park at 2-4 months following treatment. The findings regressed 12 months after treatment. None of the 31 patients treated with ethambutol developed EON (ref.²⁵). There is currently no effective treatment for EON. However, when EON was diagnosed early, visual function was improved in 30-64% of patients following immediate discontinuation of ethambutol. A full recovery is quite rare²⁶⁻³⁰.

CONCLUSION

Even though EON is not an unknown complication, new cases still occur and, unfortunately, with an irreversible course. Therefore, it is important to draw attention to this complication constantly and to consider it in ophthalmologists' surgeries.

Ethics approval and consent to participate

The present study was performed according to the Declaration of Helsinki and was approved by the internal ethics committee of the Ophthalmology Clinic Jana Leštáka (Prague, Czech Republic). All details, medical records, figures, medical history or test results were used with the written consent for publication from the patient, which is available from the corresponding author on reasonable request. All data used were anonymized.

Acknowledgement: Research was supported by institutional resources of Czech Technical University in Prague, Faculty of Biomedical Engineering.

Author contributions: All authors contributed to the study conception and design, material preparation, data collection and analysis; MK: the first draft of the manuscript writing; All authors read and approved the final manuscript.

Conflict of interest statement: The authors state that there are no conflicts of interest regarding the publication of this article.

REFERENCES

1. Chan RY, Kwok AK. Ocular toxicity of ethambutol. Hong Kong Med J 2006;12:56-60.

2. Carr RE, Henkind P. Ocular manifestations of ethambutol, toxic amblyopia after administration of an experimental antituberculous drug. *Arch Ophthalmol* 1962;67:566-71.
3. Woung LC, Jou JR, Liaw SL. Visual function in recovered ethambutol optic neuropathy. *J Ocul Pharmacol Ther* 1995;11:411-19.
4. Tsai RK, Lee YH. Reversibility of ethambutol optic neuropathy. *J Ocul Pharmacol Ther* 1997;13:473-77.
5. Barron GJ, Tepper L, Iovine G. Ocular toxicity from ethambutol. *Am J Ophthalmol* 1974;77:256-60.
6. Holcová B, Száhalová D. Ocular complications in ethambutol treatment. *Čs Oftal* 1975;31:256-59. (In Czech)
7. Krchnavá B, Slámová J. The toxic effect of ethambutol on tbc visual organ. *Čs Oftal* 1976;32:39-44. (In Czech)
8. Stibor V, Lachmanová J, Tomášek R. Ocular complications of antituberculous in patients with regular dialysis. *Čs Oftal* 1989;45:62-64. (In Czech)
9. Liška V, Vitvarová J. Toxic damage of optic nerve during ethambutol treatment in a chronically dialyzed patient. *Čs Oftal* 1991;47:133-37. (In Czech)
10. Základní přehled epidemiologické situace ve výskytu tuberkulózy v České republice v roce 2019. ÚZIS ČR. [cited 2021 Dec 20] Available from: <https://www.uzis.cz/res/f/008314/tbc2019-cz.pdf> (In Czech)
11. Leibold JE. The ocular toxicity of ethambutol and its relation to dose. *Ann NY Acad Sci* 1966;135:904-09.
12. Kahana L M. Toxic ocular effects of ethambutol. *CMAJ*. 1987;137:213-16.
13. Russo P A, Chaglasian M A. Toxic optic neuropathy associated with ethambutol: implications for current therapy. *J Am Optom Assoc* 1994;65:332-38.
14. Chamberlain PD, Sadaka A, Berry S, Lee AG. Ethambutol optic neuropathy. *Curr Opin Ophthalmol* 2017;28:545-51.
15. Koul PA. Ocular toxicity with ethambutol therapy: Timely recalculation. *Lung India* 2015;32:1-3.
16. Schmidt IG, Schmidt LH. Studies of neurotoxicity of ethambutol and its racemate for the rhesus monkey. *J Neuropath Exp Neurol* 1966;25:40-67.
17. Schmidt IG. Central nervous system effects of ethambutol in monkeys. *Ann NY Acad Sci* 1966;135:759-74.
18. Lessell S. Histopathology of experimental ethambutol intoxication. *Invest Ophthalmol Vis Sci* 1976;15:765-69.
19. Karnik AM, Al-Shamali MA, Fenech FF. A case of ocular toxicity to ethambutol-an idiosyncratic reaction? *Postgrad Med J* 1985;61:811-13.
20. Chawla JPS, Crisan E, Jay WM. Ethambutol chiasmal toxicity with bitemporal hemianopia. *Semin Ophthalmol* 2009;24:221-24.
21. Kho RC, Al-Obailan M, Arnold AC. Bitemporal visual field defects in ethambutol-induced optic neuropathy. *J Neuroophthalmol* 2011;31:121-26.
22. Scemama EB, Touitou V, Le Hoang P. Bitemporal hemianopia as presenting sign of severe ethambutol toxicity. *J Fr Ophthalmol* 2013;36:163-67.
23. Osaguona VB, Sharpe JA, Awaji SA, Farb RI, Sundaram AN. Optic chiasm involvement on MRI with ethambutol-induced bitemporal hemianopia. *J Neuroophthalmol* 2014;34:155-58.
24. Heng JE, Vorwerk CK, Lessell E, Zurakowski D, Levin LA, Dreyer EB. Ethambutol is toxic to retinal ganglion cells via an excitotoxic pathway. *Invest Ophthalmol Vis Sci* 1999;40:190-96.
25. Kim KL, Park S P. Visual function test for early detection of ethambutol induced ocular toxicity at the subclinical level. *Cutan Ocul Toxicol* 2016;35:228-32.
26. Lee EJ, Kim SJ, Choung HK, Kim JH, Yu YS. Incidence and clinical features of ethambutol-induced optic neuropathy in Korea. *J Neuroophthalmol* 2008;28:269-77.
27. Ezer N, Benedetti A, Darvish-Zargar M, Menzies D. Incidence of ethambutol- related visual impairment during treatment of active tuberculosis. *Int J Tuberc Lung Dis* 2013;17:447-55.
28. Kuma A, Sandramouli S, Verma L, Tewari HK, Khosla PK. Ocular ethambutol toxicity: is it reversible? *J Clin Neuroophthalmol* 1993;13:15-17.
29. Tsai RK, Lee YH. Reversibility of ethambutol optic neuropathy. *J Ocul Pharmacol Ther* 1997;13:473-77.
30. Kumar A, Dada T. Visual evoked response (VER) in ocular ethambutol toxicity. *Natl Med J India* 1999;12:193-94.