

Use of Malyugin Pupil Expansion Ring in Femtosecond Laser-assisted Cataract Surgery

Nada Jirasková^{1,4}, Pavel Rozsival^{1,4} and Jan Lešták^{2,3,4*}¹Department of Ophthalmology, University Hospital and Charles University Medical Faculty, Hradec Králové, Czech Republic²JL Clinic, V Hůrkách 1296/10, Prague, Czech Republic³Czech Technical University in Prague (Faculty of Biomedical Engineering), Czech Republic⁴Charles University (Faculty of Medicine in Hradec Kralove), Czech Republic**Abstract**

Purpose: To describe a technique that allows performing femtosecond laser-assisted cataract surgery with the LenSx laser (Alcon) in patients with poor or non dilating small pupils.

Methods: Case report describing new surgical technique.

Results: The primary and secondary incisions were made manually and the anterior chamber was filled with ophthalmic viscosurgical device (OVD). The Malyugin pupil expansion device (Microsurgical Technology) was inserted through the main port incision via the injector. The OVD was removed and all incisions were hydrated. Laser capsulorhexis and lens fragmentation was performed after docking. Subsequent phacoemulsification, intraocular lens (IOL) implantation and the Malyugin ring removal was performed in the usual fashion.

Conclusions: Use of the Malyugin ring is a reliable and stable method of maintaining an adequate surgical pupil diameter both for femtosecond laser assisted capsulotomy and lens fragmentation with Lenx laser and subsequent phacoemulsification and IOL implantation.

Keywords: Femtosecond laser-assisted cataract surgery; Malyugin ring; Surgical technique

Introduction

Non dilating narrow pupils are a challenge for cataract surgeons. The Malyugin pupil expansion device (Microsurgical Technology) has several advantages over traditional iris retractor hooks or other pupil dilating devices [1]. This is a disposable, square shaped implant, made of polypropylene with four circular scrolls that engage the pupillary margin at equidistant points providing a balanced stretch. It can be implanted and explanted through microincision with an injector system [2,3].

The femtosecond laser offers many possibilities for improving cataract surgery. The method has already shown excellent results for precise and self-sealing corneal incisions, highly circular, strong, and accurate capsulotomies and safer phacofragmentation and subsequent phacoemulsification [4-8]. Femtosecond laser-assisted cataract surgery (FLACS) is usually performed under topical anesthesia, with a docking system that involves a contact lens with a circumferential suction skirt distributing pressure evenly on the cornea. Because FLACS relies on anterior segment imaging for laser pattern mapping, all patients require sufficient dilation of the pupil. Furthermore, femtosecond lens fragmentation is more effective in eyes with large pupils because more lens volume can be softened, therefore decreasing the required US phacoemulsification application during nucleus removal. Using the Malyugin ring we have achieved excellent results with FLACS in patients with small pupils, that were previously considered to be poor candidates for this procedure.

Case Report - Surgical Technique

The LenSx (Alcon Laboratories, Fort Worth, TX) was installed adjacent to the Infiniti phacoemulsification machine (Alcon, Fort Worth, TX) and the operating microscope. Then the patient could be easily moved on a bed between the two systems. The eye was prepared similar to preparation for standard cataract surgery. Povidone-iodine

solution (10 mg/ml) was used for peri-orbital skin antisepsis (eyelids, nose, cheek, eyebrow, and forehead). The eyelashes were kept out of the surgical field with a sterile plastic tape and the eyelids were retracted with a Lieberman stainless steel speculum. Povidone-iodine 5 % solution was then applied liberally for irrigation of the conjunctival sac. A 2.2 mm tunnel incision was created by metal ophthalmic knife (ClearCut™ HP2, Alcon Laboratories, Fort Worth, TX) and 2 side-port incisions using a 30-degree metal ophthalmic knife (Alcon Laboratories, Fort Worth, TX). Anterior chamber was filled with cohesive ophthalmic viscosurgical device (Provisc, Alcon Laboratories, Fort Worth, TX). Malyugin ring was implanted using an injector placed in the anterior chamber and the ring was expelled from it by pressing on the thumb button. Then, the leading eyelet was engaged onto the iris followed by the lateral 2 eyelets and finally the trailing eyelet with the help of iris manipulator. Anterior chamber was washed thoroughly (bimanual irrigation/aspiration) not to leave any discontinuity in and not to disturb subsequent femto-procedure. All incisions were hydrated to achieve water-tightness. The patient was swiveled on a bed under the laser. Docking with new SoftFit™ patient interface was without any problems and wounds for Malyugin ring implantation were not changed or leaky. After docking the dimensions of the anterior chamber and the lens were measured with an integrated optical coherence tomography imaging system. The results were displayed to the surgeon on the geographic user interface for verification (Figure 1). A 4.8 mm

***Corresponding author:** Jan Lešták, MD, PhD, FEBO, JL Clinic, V Hůrkách 1296/10, Prague, Czech Republic, E-mail: lestak@seznam.cz

Received October 11, 2013; **Accepted** December 03, 2013; **Published** December 10, 2013

Citation: Jirasková N, Rozsival P, Lešták J (2013) Use of Malyugin Pupil Expansion Ring in Femtosecond Laser-assisted Cataract Surgery. J Clin Exp Ophthalmol 4: 312. doi: [10.4172/2155-9570.1000312](http://dx.doi.org/10.4172/2155-9570.1000312)

Copyright: © 2013 Jirasková N, et al. This is an open-access article distributed under the terms of the Creative Commons Attribution License, which permits unrestricted use, distribution, and reproduction in any medium, provided the original author and source are credited.

diameter circular capsulotomy was performed by scanning a cylindrical pattern starting 300 μm below the anterior capsule and ending at 300 μm above the capsule (Figure 2). Capsulotomy was followed by nucleus fragmentation (Figure 3). Because with the LenSx system the docking procedure is a “non-sterile work” for surgeon, the surgeon changed gloves and gown after laser. After laser-assisted capsulotomy and fragmentation, patient was rotated under operating microscope and a new preparation for cataract surgery (peri-orbital skin antisepsis, sterile plastic tape and speculum) was performed. The anterior capsulotomy was removed with forceps. Hydrodissection, phaco of the lens fragments, and bimanual irrigation/aspiration (I/A) of the cortex were performed. After the anterior chamber and capsular bag were reinflated with OVD, a hydrophobic intraocular lens was injected into the capsular bag without enlarging the corneal tunnel. Malyugin ring was removed under OVD to protect the corneal endothelium. The trailing scroll was disengaged using the iris manipulator, and positioned on the injector plate. The whole device was pulled back into the inserter and out of the anterior chamber. Removal of the OVD was performed using bimanual I/A, and all wounds were hydrated. Antibiotic a steroid drops (Tobradex gtt, Alcon Pharmaceuticals) were installed and the eye was covered with a patch.

Discussion

The femtosecond lasers cause tissue disruption with its ultrafast

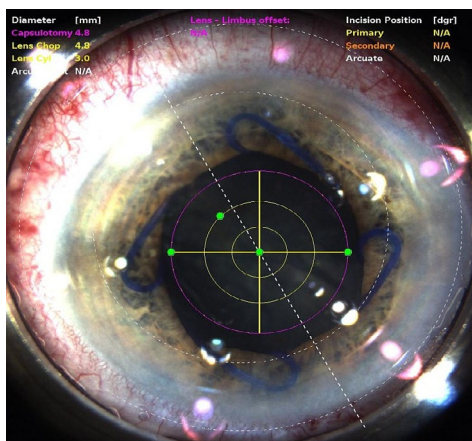


Figure 1: Femtosecond laser procedure: The geographic user interface for limbus and lens centration.

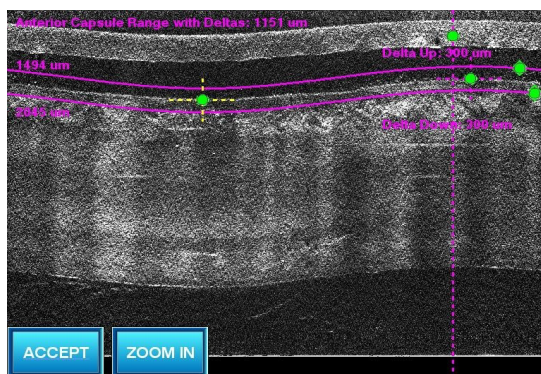


Figure 2: Femtosecond laser procedure: Circular OCT scan of the lens and anterior capsule for verification of the capsulotomy.

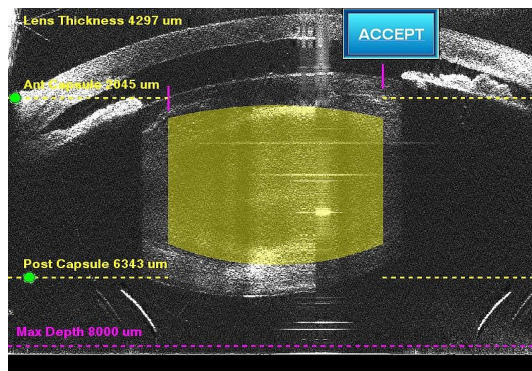


Figure 3: Femtosecond laser procedure: Linear OCT scan of the lens for the verification of the nucleus fragmentation.

pulses in the range of 10-15 second focused to 3 μm with an accuracy of 1 μm. Because these lasers function nearly at an infrared wavelength, they are not absorbed by optically clear tissues [9,10]. While femtosecond lasers were previously approved for use in lamellar corneal surgery, the modality was approved for cataract surgery in 2010, and up to now there are several laser platforms available. LenSx (Alcon, Fort Worth, TX) is now approved for lens fragmentation, anterior capsulotomy and corneal incisions. Although the steps for each laser platform vary, they all require appplanation of the cornea with a docking system. The docking system increases intraocular pressure (IOP), although reportedly less than seen in femtosecond laser refractive surgery [11]. The perfect docking is essential for anterior segment imaging. LenSx utilizes Fourier-domain optical coherence tomography (FD-OCT). This step is required to find anatomical landmarks for laser pattern mapping. In LenSx docking you need to accomplish two separate mechanical tasks: immobilization of the globe and contact lens appplanation of the cornea. A single docking device has to achieve simultaneously both two different and independent parts, making docking more challenging. However, our results have proved that perfect LenSx docking could be accomplished on corneas with incisions. Docking with new SoftFit patient interface is easier than previously.

Other problem could be gas bubbles in the anterior chamber during capsulotomy and lens fragmentation. Sometimes, despite perfect docking, gas bubbles escape from the lens into the anterior chamber during the process of capsulotomy. These bubbles can block subsequent shots and result in an incomplete capsulotomy cut. They may also reduce the visualization of capsulotomy edges. A large pupil allows clear visualization of the anterior segment by the surgeon and enables management of this possible problem.

For those, who perform femtosecond laser portion of the surgery in the other room, not in the operating room with phacoemulsification machine, it may appear moving patient between separate places rather uncomfortable. At our department we have both machines in the same operating room and we just swivel the patient between procedures on the same bed.

Malyugin ring gives uniform, gentle dilation to the pupil with lack of excessive stress at the points of pupillary margins and its reliable clamping mechanism keeps the position of the ring stable throughout procedure. Because of the way the iris drapes over the straight sides of the square device, it produces a round rather than a square pupil configuration. Other advantage of the Malyugin ring is lack of any sharp ends which can damage intraocular tissue. In our case use of this

device was a reliable and stable method of maintaining an adequate surgical pupil diameter both for femtosecond laser assisted capsulotomy and lens fragmentation and subsequent phacoemulsification and intraocular lens implantation.

To our knowledge, the technique of using the Malyugin ring in femtosecond laser-assisted cataract surgery with the LenSx® laser was already performed but has not been described yet. The use of Malyugin ring has been recently described in 27 eyes, where FLACS was performed with the Catalys Precision Laser System (Optimedica Corp.) [12]. Our technique differs from the technique described by Conrad-Hengerer et al. in two aspects: they have performed the whole procedure with only one sterile covering with the sterility maintained during the whole process and the OVD was not removed from the anterior chamber before laser procedure [12].

Femtosecond laser-assisted cataract surgery is relatively new procedure, but with great potential for further improvement. Ongoing research should be performed to evaluate the long-term outcomes, safety and visual rehabilitation.

Conflict of Interest

None of the authors has a financial or proprietary interest in any product mentioned.

Funding

Supported by Charles University in Prague - Programme P37/07 (PRVOUK).

References

1. Malyugin B (2007) Small pupil phaco surgery: a new technique. *Ann Ophthalmol (Skokie)* 39: 185-193.
2. Wilczynski M, Wierzchowski T, Synder A, Omulecki W (2013) Results phacoemulsification with Malyugin ring in comparison with manual Iris stretching with hooks in eyes with narrow pupil. *Eur J Ophthalmol* 23: 196-201.
3. Chang DF (2008) Use of Malyugin pupil expansion device for intraoperative floppy-iris syndrome: Results in 30 consecutive cases. *J Cataract Refract Surg* 34: 835-841.
4. Moshirfar M, Churgin DS, Hsu M (2011) Femtosecond Laser-Assisted Cataract Surgery: A Current Review. *Middle East Afr J Ophthalmol* 18: 285-291.
5. Nagy Z, Takacs A, Filkorn T, Sarayba M (2009) Initial clinical evaluation of an intraocular femtosecond laser in cataract surgery. *J Refract Surg* 25: 1053-1060.
6. Bali SJ, Hodge C, Lawless M, Roberts TV, Sutton G (2012) Early experience with the femtosecond laser for cataract surgery. *Ophthalmology* 119: 891-899.
7. Friedman NJ, Palanker DV, Schuele G, Andersen D, Marcellino G, et al. (2011) Femtosecond laser capsulotomy. *J Cataract Refract Surg* 37: 1189-1198.
8. Nagy ZZ, Kránitz K, Takacs AI, Miháltz K, Kovács I, et al. (2001) Comparison of intraocular lens decentration parameters after femtosecond and manual capsulotomies. *J Refract Surg* 27: 564-569.
9. Sugar A (2002) Ultrafast (femtosecond) laser refractive surgery. *Curr Opin Ophthalmol* 13: 246-249.
10. Tackman RN, Kuri JV, Nichamin LD, Edwards K (2011) Anterior capsulotomy with an ultrashort-pulse laser. *J Cataract Refract Surg* 37: 819-824.
11. He L, Sheehy K, Culbertson W (2011) Femtosecond laser-assisted cataract surgery. *Curr Opin Ophthalmol* 22: 43-52.
12. Conrad-Hengerer I, Hengerer FH, Schultz T, Dick HB (2013) Femtosecond laser-assisted cataract surgery in eyes with a small pupil. *J Cataract Refract Surg* 39: 1314-1320.

Citation: Jirasková N, Rozsival P, Lešták J (2013) Use of Malyugin Pupil Expansion Ring in Femtosecond Laser-assisted Cataract Surgery. J Clin Exp Ophthalmol 4: 312. doi: [10.4172/2155-9570.1000312](https://doi.org/10.4172/2155-9570.1000312)

Submit your next manuscript and get advantages of OMICS Group submissions

Unique features:

- User friendly/feasible website-translation of your paper to 50 world's leading languages
- Audio Version of published paper
- Digital articles to share and explore

Special features:

- 300 Open Access Journals
- 25,000 editorial team
- 21 days rapid review process
- Quality and quick editorial, review and publication processing
- Indexing at PubMed (partial), Scopus, EBSCO, Index Copernicus and Google Scholar etc
- Sharing Option: Social Networking Enabled
- Authors, Reviewers and Editors rewarded with online Scientific Credits
- Better discount for your subsequent articles

Submit your manuscript at: www.editorialmanager.com/clinicalgroup