

## **FMRI in a patient with pigmentary retinal dystrophy. Case report.**

Jan Lestak<sup>1,2,3\*</sup>, Jiri Zahlava<sup>1</sup>, Jaroslav Tintera<sup>1</sup>, Nada Jiraskova<sup>3</sup> and Leos Navratil<sup>2</sup>

1.JL Clinic, V Hurkach 1296/10, Prague, Czech Republic

2.Czech Technical University in Prague (Faculty of Biomedical Engineering), Czech Republic

3.Charles University (Faculty of Medicine in Hradec Kralove), Czech Republic

### **Abstract**

**Objective:** The aim is to demonstrate the changes in functional magnetic resonance imaging (FMRI) of the brain in a patient with pigmentary retinal dystrophy of both eyes, which is the most often discussed topic in relation to the bionic eye.

**Patient and methods of examination:** The authors report the case of a 63-year-old patient with pigmentary retinal dystrophy of both eyes. The patient underwent a complete eye examination, including visual functions, photographs and functional magnetic resonance imaging. (FMRI).

**Results:** Visual acuity of the right and left eye was 0.2 and 0.3 respectively. Visual field of the right and left eye – concentric narrowing to 10 and 5 degrees respectively. Despite the above visual functions, the visual centre of the brain did not show any activity on FMRI.

**Conclusion:** Our work demonstrates that damage to the retinal cells is also associated with damage of the visual cortex in the brain. This also explains the relative failure of "bionic eyes".

**Keywords:** pigmentary retinal dystrophy, functional magnetic resonance imaging, bionic eye

**Corresponding author:** Jan Lestak, doc, MD, PhD, MSc, FEBO, MBA, LLA, DBA, FAOG  
JL Clinic, V Hurkach 1296/10, 158 00 Prague 5, Czech Republic, E-mail:  
[lestak@seznam.cz](mailto:lestak@seznam.cz)

### **Introduction**

Damage to the axons of the central and peripheral nervous system leads to their degeneration. This degeneration can be anterograde or retrograde, and may take place even in the visual system. In 1963, retrograde transsynaptic degeneration (RTD) in primates after right-sided occipital lobectomy with subsequent ipsilateral atrophy of the lateral geniculate body and homolateral atrophy of retinal ganglion cells was the first recorded case. [22] The first literary record of RTD in human medicine dates back to 1950 and was presented by Haddock from Berlin. [7] However, it is not known whether the damage was a result of occipital lobe lesion. The first literary mention of anterograde transsynaptic degeneration (ATD) in ophthalmology is associated with the names of Haseltine et al. [8]

More intensive experimental research in this area started 15 years ago in the laboratories of Vickers et al. [23], Crawford et al. [3] and Yucel et al. [24] The first work on ATD of the

visual pathway in humans comes from Boucard et al. [2], who investigated the density of grey matter in visual cortex of patients with glaucoma and age-related macular degeneration on magnetic resonance.

Records on the use of functional magnetic resonance imaging (fMRI) in the diagnostics of ATD in clinical ophthalmology are scarce in recent worldwide literature. [4, 5]

Most of the works in this area come from the workplace of the first author of this case report. [9-15, 20]

The aim of this work is to demonstrate the damage of the visual cortex in the brain of a patient affected by pigmentary retinal dystrophy of both eyes, which is the most often discussed topic in relation to the bionic eye.

## **Material and Methods**

### **Patient's characteristics**

The patient, born in 1952, was followed since May 2002 for haemeralopia, which had been present since his school years. On examination, we discovered an advanced form of pigmentary retinal dystrophy of both eyes. The patient reported no other disease. His parents had no eye disorders. The elder brother of the patient has the same retinal disease. The younger brother died a few years ago and did not suffer from any eye disorders. The patient's daughter is healthy, as is her son. In November 2002, we performed cataract surgery in our department on the right eye and, in February 2003, also on the left eye. Vision was 0.4 and 0.6 respectively after the surgeries. In December 2015, the patient was examined at his request. Subjectively, he reported a decrease in visual acuity and visual field narrowing. He also stated that, for the past three years, he has been applying latanoprost into both eyes.

### **Functional MR imaging (fMRI)**

Functional MRI examinations were carried out on the Philips Achieva 3T TX MR system (Philips Healthcare, Eindhoven, Netherlands) with a magnetic field strength of 3 Tesla, using the blood oxygen level dependent (BOLD) contrast. A standard 32-channel head coil was used and each measurement was performed with gradient-echo echo-planar imaging sequence (TR/TE = 3000/30 ms, spatial resolution of  $2 \times 2 \times 2 \text{ mm}^3$ ). Optical stimulation was performed by a black/white checkerboard alternated with its negative image with a frequency of 2 Hz. The visual size of the black and white checkerboard was  $25.8 \times 16.2$  degrees. The measurements consisted of a sequence of five 30-second active phase periods and five resting periods of the same length (each of 10 dynamic scans). During the resting phase, a static crosshair situated in the centre of the visible field was projected for the view fixation. In total, every measurement included 100 dynamic scans and took 5 minutes. Each eye was examined by means of separate fMRI measurement (LE, RE) and also one control measurement was performed by stimulating both eyes together (LE+RE).

Evaluation of the task-related fMRI was done using General Linear Model (GLM) in SPM12. After standard preprocessing (Realignment, Normalisation to MNI space, smoothing to  $6 \times 6 \times 6 \text{ mm}^3$ ), GLM statistic with final  $p=0.05$  with Family Wise Error (FWE) correction was done. Functional connectivity was also studied using the CONN software package (version 15, Gabrieli Lab. McGovern Institute for Brain Research, Massachusetts Institute of Technology). Connectivity maps were calculated from the same data as task-related fMRI, where the condition of the stimulation scheme was defined as a confound variable. Seed-to-voxel analysis was used to compare the connectivity in relevant preselected brain areas

(Intracalcarine cortex, inferior lateral occipital cortex, Heschl's gyrus) between our patient and a typical healthy volunteer of similar age.

### Results

In December 2015, the patient was comprehensively examined and objective findings during this examination included an undisturbed anterior segment of both eyes, deeper anterior chambers, unobstructed pupils and missing lenses. Artificial intraocular lenses were implanted in the remnants of the capsules. The vitreous body shows clumping of collagen fibres. The papilla is round, circumscribed, waxy yellowish; the central vessels are threadlike, some are disappearing. The neuroretina is grey in the macula with absent foveolar reflex, surrounded by chorioretinal atrophy, dense retinal pigment hyperplasia shaped as bone spicules extending from the arcades. Vision 0.2 and 0.3. Perimeter: bilateral concentric narrowing to ten and five degrees respectively. The results of the clinical examination are documented in Figures 1, 2, 3.

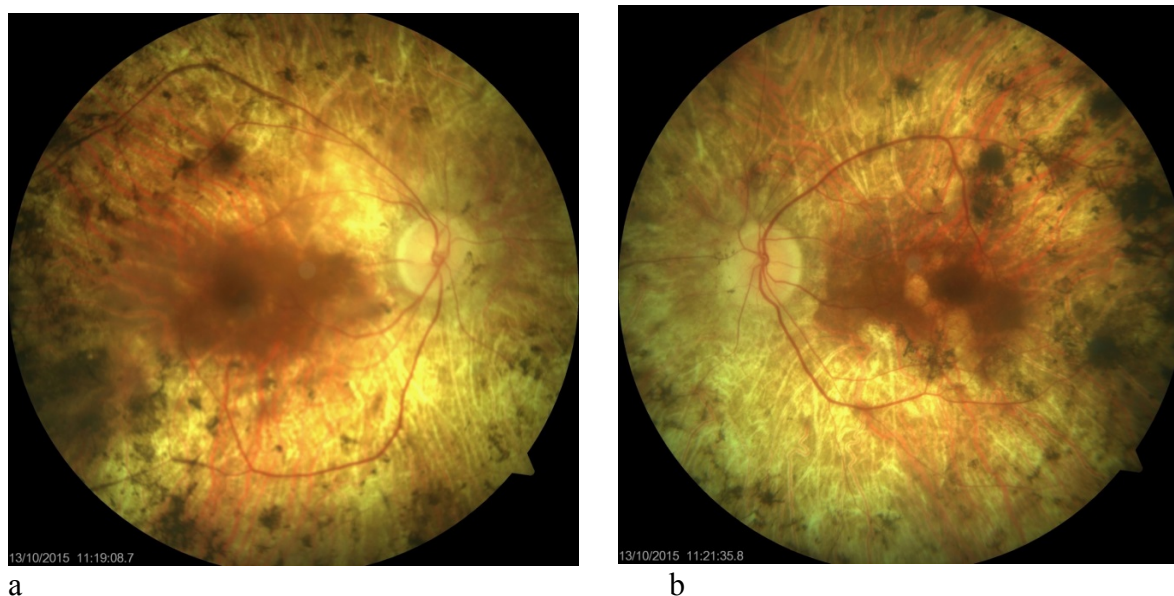


Figure 1: Colour image of the fundus of the right eye a), left eye b)

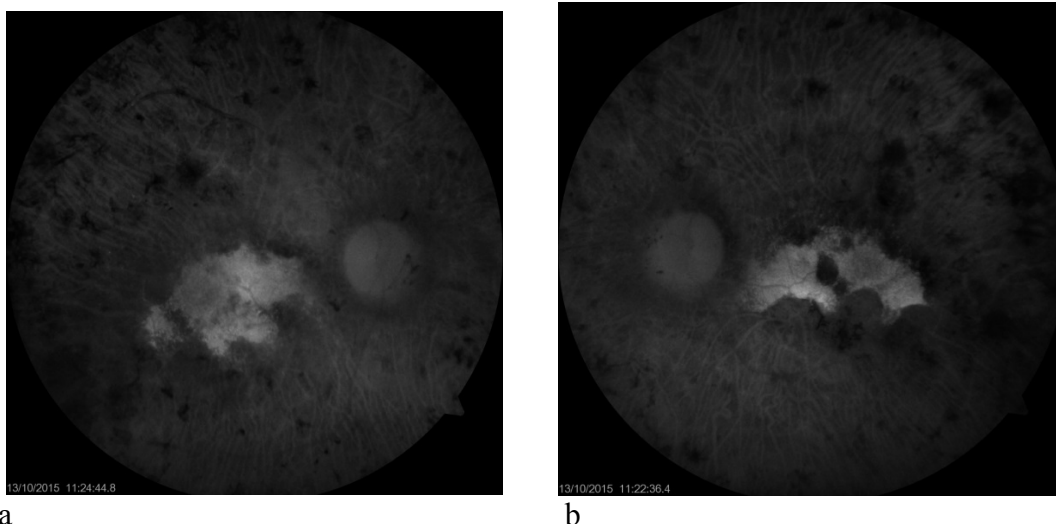


Figure 2: Fundus autofluorescence imaging of the right eye a), fundus autofluorescence imaging of the left eye b)

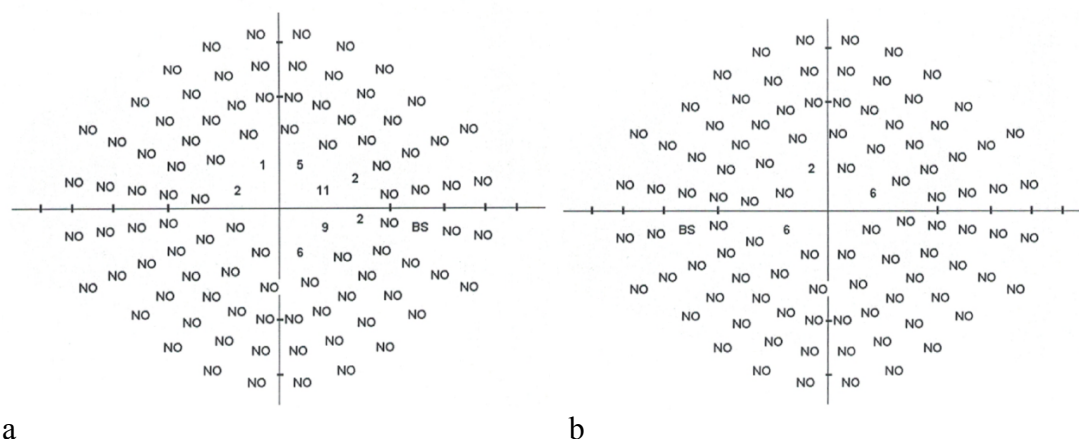


Figure 3: Field of vision of the right eye a), left eye b)

Evaluation of fMRI showed no activation of the visual cortex (see Figure 4, at  $p = 0.05$  FWE). No activation was shown even at a less statistically significant threshold ( $p = 0.001$ , no correction). The absence of any statistically significant activation cannot be explained by a lower compliance of the patient (motion artefacts), because realignment results show amplitude of brain shift during the measurements below 1 mm, and the rotation below  $1^\circ$ . The reason for the zero activation of the visual cortex could therefore be the absence of a signal at the insertion of the optical path. Therefore, a comparison of functional connectivity independent of stimulation was made in a healthy volunteer and in a reference area (both sides of Heschl's gyrus).

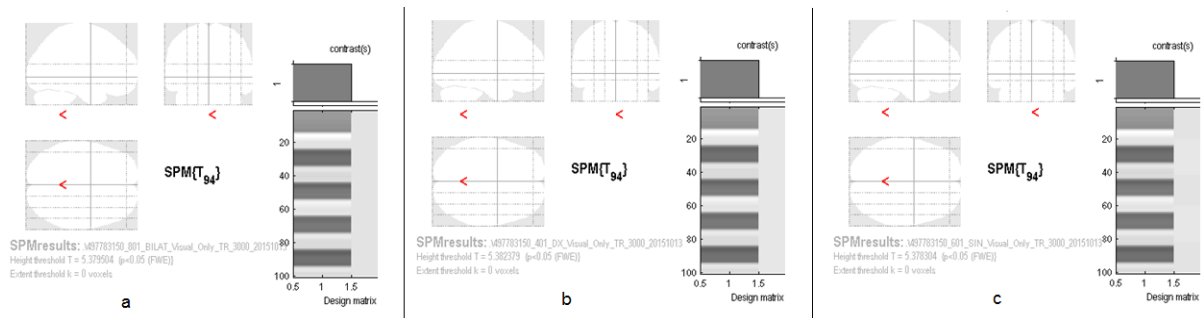


Figure 4: No fMRI activity after stimulation of both eyes a), the right eye b), the left eye c) at  $p = 0.05$  FWE.

The resulting functional connectivity maps are shown in Figure 5 for the areas of the visual cortex and Figure 6 for Heschl's gyrus. While a huge difference in connectivity can be clearly seen in the visual cortex, the auditory cortex provides very similar images.

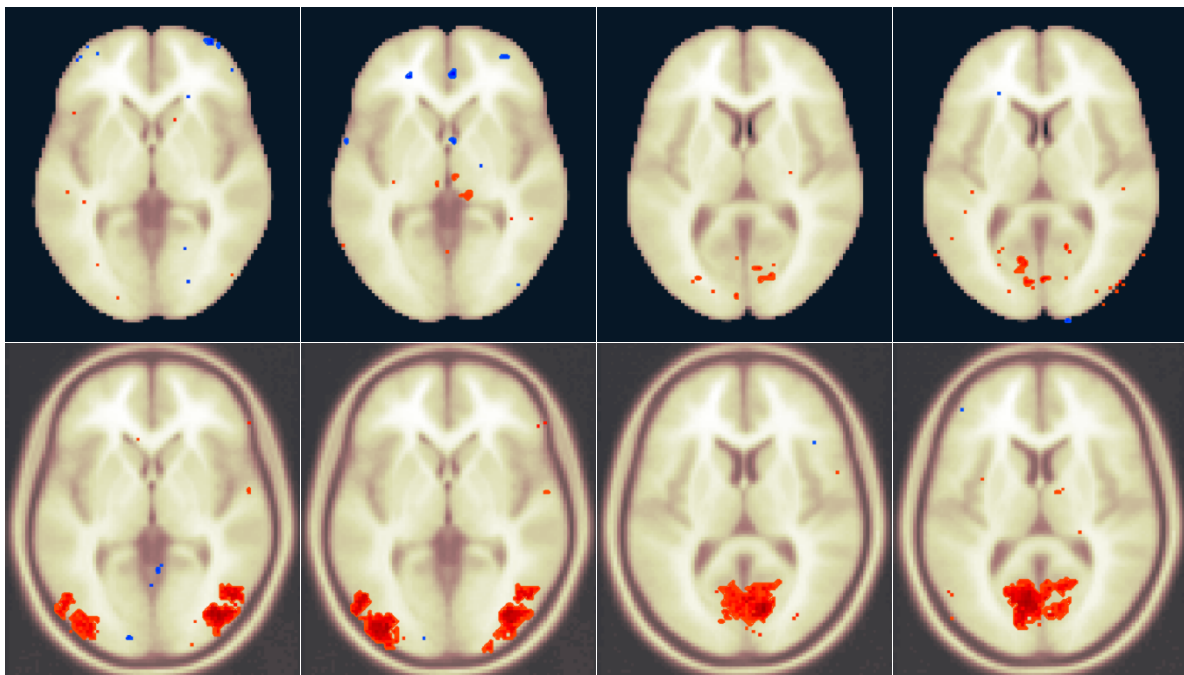


Figure 5: Maps of functional connectivity of the patient (top row) and a healthy volunteer from the same type of measurement. Starting seeds are placed into a) the right inferior lateral occipital cortex, b) left inferior lateral occipital cortex, c) the right intracalcarine cortex, d) left intracalcarine cortex (correlation threshold of 0.6).

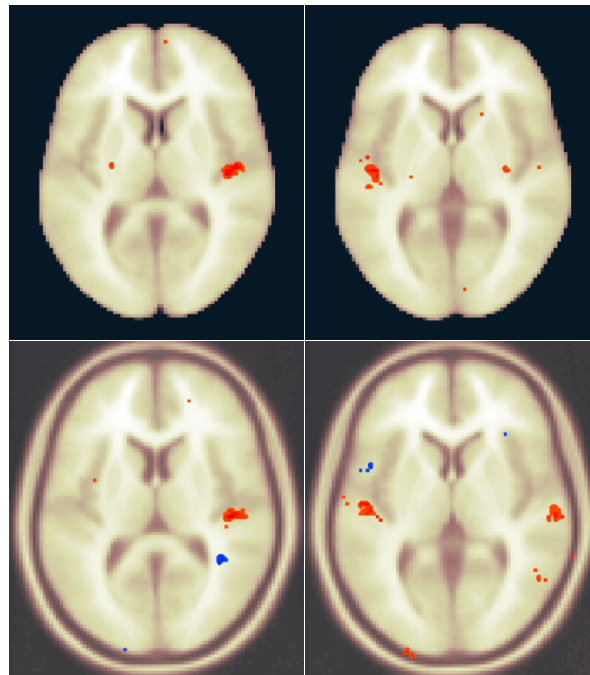


Figure 6: Again maps of functional connectivity of the patient (top row) and a healthy volunteer. Starting seeds are placed in the a) right and b) left Heschl's gyrus (correlation threshold of 0.6)

## Discussion

Pigmentary retinal dystrophy is a disease that affects the rods and cones and pigment epithelium located underneath. The inner nuclear and plexiform, ganglion cells, and nerve fibre layer undergo degeneration and replacement with gliotic tissue, but the changes are much more variable and may not be evident until the later stages of the disease. [1]

Our long experience with electrophysiology of vision shows that already in the early stages of the disease, the central retinal structures and retinal ganglion cells are also affected.

Consequently, there is also damage to the optic nerve and visual cortex of the brain.

These electrophysiological findings of damage to the visual pathway are also confirmed in the works aimed at the measurement of diffusion tensor imaging. [17, 21]

There are different theoretical possibilities of electrical stimulation of the visual pathway. The electrodes may be implanted in epiretinal, subretinal or suprachoroidal spaces and can therefore stimulate retinal ganglion cells. Similarly, the axons of these cells can also be stimulated by electrodes placed in the cuff enveloping the optic nerve. Another level of stimulation can include the lateral geniculate body, which can be stimulated by deep electrodes or newly by multiple microelectrodes. Similarly, the visual cortex can be stimulated by surface or deep electrodes according to Philip et al. [18]

The prerequisites for maintaining visual functions are the intact visual pathway and subcortical and cortical centres in the brain.

Over the recent few years, our works on fMRI have shown that the damage to the retinal cells is also associated with the damage of the visual cortex of the brain. Progression of retinal disease is associated with the decline in fMRI activity and brain connectivity. This also explains the relative failure of "bionic eyes".

If the damage lasts for more than 3-5 years, restitution of cortical cells cannot be expected, but precisely the opposite. Like the bionic eye, the implantation of stem cells into damaged retinas will not have a significant effect, because the target neuron will not be able to process possible electrical response.

After many years of research, the functional bionic eye came to light. The American company, Second Sight Medical Products, and its The Argus® II Retinal Prosthesis System programme (referred to as Argus II), which concentrates on stimulation of the retina, has already helped many patients with visual impairments. For example, the company developed a retinal implant with 60 electrodes or glasses with special miniature cameras. The company has already received permission to sell the bionic eye on the European market ["A Bionic Eye That restores Sight ". The Atlantic. 31 August 2014. Retrieved 5 January 2015]. By March 2014, the Argus II system was implanted in more than 80 people. The best results were achieved in patients with decreased visual acuity 20/1260 (0.015), which corresponds to the ability to count the fingers in front of one's eye. Vision improved to 20/1000 after the use of Argus II. [6]

Our patient had visual acuity of 0.2 and 0.3 respectively. As a result, much better than the patients who had the Argus II implanted. Despite this, no FMRI response was obtained in our patient.

## **Conclusion**

Our works demonstrate that damage to the retinal cells is associated with damage to the visual cortex of the brain. Progression of retinal disease is associated with the decline in fMRI brain activity. This also explains the relative failure of "bionic eyes".

## **Acknowledgements**

Supported in part by research project P37/07 (Prvouk) of the Ministry of Health, Prague, Czech Republic

## **References**

1. Bloome MA, Garcia ChA, : Manual of retinal and choroidal dystrophies. Appleton-Century-Crofts New York, 1981, p. 129, ISBN-10: 0838561268
2. Boucard CC, Hernowo AT, Maguire RP, Jansonius NM, Roerdink JB, Hooymans JM, Cornelissen FW. Changes in cortical grey matter density associated with longstanding retinal visual field defects. Brain, 2009;132:1898–1906
3. Crawford MLJ, Harwerth RS, Smith EL, Shen F, Carter-Dawson L. Glaucoma in Primates: Cytochrome Oxidase Reactivity in Parvo- and Magnocellular Pathways. Invest Ophthalmol Vis Sci 2000;41:1791-1802

4. Duncan RO, Sample PA, Weinreb RN, Bowd C, Zangwill LM. Retinotopic Organization of Primary Visual Cortex in Glaucoma: Comparing fMRI Measurements of Cortical Function with Visual Field Loss. *Prog Retin Eye Res* 2007;26(1):38-56

5. Duncan RO, Sample PA, Weinreb RN, Bowd C, Zangwill LM. Retinotopic organization of primary visual cortex in glaucoma: a method for comparing cortical function with damage to the optic disc. *Invest Ophthal Vis Sci* 2007;48(2):733-744

6. Fernandes, R.A.; Diniz, B.; Ribeiro, R.; Humayun, M. Artificial vision through neuronal stimulation. *Neuroscience Letters*, 2012;519 (2):122–128

7. Haddock JN, Berlin L. Transsynaptic degeneration in the visual system; report of a case. *Arch Neurol Psychiatry*, 1950;64(1):66-73

8. Haseltine EC, DeBruyn EJ, Casagrande VA. Demonstration of ocular dominance columns in Nissl-stained sections of monkey visual cortex following enucleation. *Brain Res* 1979;176:153-158

9. Lestak J, Tintera J, Kyncl M, Svata Z, Obenberger J, Saifrtova A. Changes in the Visual Cortex in Patients with High-Tension Glaucoma. *J Clin Exp Ophthalmol*, 2011; S4 doi: [10.4172/2155-9570.S4-002](https://doi.org/10.4172/2155-9570.S4-002)

10. Lestak J, Tintera J, Ettlner L, Nutterova E, Rozsival P. Changes in the Visual Cortex in Patients with Normotensive Glaucoma. *J Clin Exp Ophthalmol*, 2012;S:4 <http://dx.doi.org/10.4172/2155-9570.S4-008>

11. Lestak J, Tintera J, Svata Z, Ettlner L, Rozsival P. Brain Activations in fMRI induced by Color Stimulation in Patients with Normotensive Glaucoma. *J Clin Exp Ophthalmol*, 2012;3:8 <http://dx.doi.org/10.4172/2155-9570.1000250>

12. Lestak J, Tintera J, Karel I, Svata Z, Rozsival P. FMRI in Patients with Wet Form of Age-Related Macular Degeneration. *Neuro-Ophthalmology*, 2013;37:192–197

13. Lestak J, Tintera J, Kyncl M, Svata Z, Rozsival P. High Tension Glaucoma and Normal Tension Glaucoma in Brain MRI *J Clin Exp Ophthalmol*, 4;2013:4. <http://dx.doi.org/10.4172/2155-9570.1000291>

14. Lestak J, Tintera J, Kalvoda J, Svata Z, Kalvodova B, Karel I, Rozsival P. FMRI after internal limiting membrane peeling for symptomatic lamellar macular hole and macular pseudohole surgery. *International Journal of Applied Research*, 2014;4:379-382

15. Lestak J, Tintera J and Rozsival P. FMRI and ocular dominance. *IJSR – International Journal of Scientific Research*, 2014, 3(10), 293-296, ISSN No 2277-8179, DOI : [10.15373/22778179](https://doi.org/10.15373/22778179)

16. Nguyen TH, Stievenart JL, Saucet JC, LeGargasson JF, Cohen YS, Pelegriani-Issac M, Burnod Y, Iba-Zizen MT, Cabanis EA. Cortical response to age-related macular degeneration (Part II). Functional MRI study. *J Fr Ophthalmol*, 2004;27:72-86

17. Ohno N , Murai H , Suzuki Y , Kiyosawa M , Tokumaru AM , Ishii K , OhnoMatsui



- K . Alteration of the optic radiations using diffusion tensor MRI in patients with retinitis pigmentosa. *Br J Ophthalmol.* 2015;99(8):10514. doi: 10.1136/bjophthalmol2014305809
18. Philip M. Lewis PM, Ackland HM, Lowery AJ, Rosenfeld JV. Restoration of vision in blind individuals using bionic devices: A review with a focus on cortical visual prostheses. *Brain Research*, 2015;1595:51-73
19. Qing G, Zhang S, Wang, B, Wang N. Functional MRI Signal Changes in Primary Visual Cortex Corresponding to the Central Normal Visual Field of Patients with Primary Open-Angle Glaucoma. *Invest Ophthalmol Vis Sci*, 2010;51(9):4627-4634
20. Saifrtová A, Lešták J, Tintěra J, Svatá Z, Ettler L, Rozsival P and Veselá-Florová Z: Colour vision defect in patients with high-tension glaucoma. *J Clin Exp Ophthalmol* 2012, 3:9 <http://dx.doi.org/10.4172/2155-9570.1000252>. ISSN: 2155-9570
21. Schoth F, Burgel U, Dorsch R, Reinges MH, Krings T. Diffusion tensor imaging in acquired blind humans. *Neurosci Lett.* 2006;398(3):178-182
22. Van Buren JM. Trans-synaptic retrograde degeneration in the visual system of primates. *J Neurol Neurosurg Psychiatry*, 1963;26:402-409
23. Vickers JC, Hof PR, Schumer RA, Wang RF, Podos SM, Morrison JH. Magnocellular and parvocellular visual pathways are both affected in a macaque monkey model of glaucoma. *Aust NZ J Ophthalmol.* 1997;25:239-243
24. Yucel Y, Zhang Q, Weinreb RN, Kaufman PL, Gupta N. Effects of retinal ganglion cell loss on magno-, parvo-, koniocellular pathways in the lateral geniculate nucleus and visual cortex in glaucoma. *Progress in Retinal and Eye Research*, 2003;22:465-481