

**OMICS PUBLISHING GROUP/Clinical**  
**Functional magnetic resonance in binasal hemianopsia.**  
 --Manuscript Draft--

<b>Manuscript Number:</b>	CLINICALGROUP-15-571R1
<b>Full Title:</b>	Functional magnetic resonance in binasal hemianopsia.
<b>Short Title:</b>	
<b>Article Type:</b>	Case Report
<b>Section/Category:</b>	Journal of Clinical & Experimental Ophthalmology
<b>Keywords:</b>	complete binasal hemianopsia; fMRI, RNFL, GCC, tumor in the pineal region and the third cerebral ventricle
<b>Corresponding Author:</b>	Jan Lešták  CZECH REPUBLIC
<b>Corresponding Author Secondary Information:</b>	
<b>Corresponding Author's Institution:</b>	
<b>Corresponding Author's Secondary Institution:</b>	
<b>First Author:</b>	Jan Lešták
<b>First Author Secondary Information:</b>	
<b>Order of Authors:</b>	Jan Lešták Jaroslav Tintera Jiri Zahlava Martin Sverapa Pavel Rozsival
<b>Order of Authors Secondary Information:</b>	
<b>Manuscript Region of Origin:</b>	CZECH REPUBLIC
<b>Abstract:</b>	The authors report a case of binasal hemianopia in a 34-year-old female who, at the age of 22 years, underwent resection of a pinealoma located at the 3rd ventricle. Less than a year after the surgery, partial visual field losses occurred. Examination of retina, retinal nerve fiber layer (RNFL) as well as examination of the ganglion cell complex (GCC) excluded a pregeniculate lesion. Functional magnetic resonance imaging (fMRI) responses evoked by both bi- and monocular stimulation confirmed our finding of reduced activity in the visual cortex corresponding to the damage in a portion of the visual pathway.
<b>Suggested Reviewers:</b>	
<b>Opposed Reviewers:</b>	
<b>Response to Reviewers:</b>	

Dear colleagues,

I would like to ask you to publish the manuscript: Lestak J, Tintera J, Zahlava J, Sverepa M, Rozsival P. Functional magnetic resonance in binasal hemianopia. Due to the fact that this report has been questioned, we decided to reopen the case, provide additional photo documentation and verify the visual field changes using functional magnetic resonance (fMRI).

Best regards,

Jan Lestak

## **Functional magnetic resonance in binasal hemianopsia.**

Jan Lestak<sup>1,2,3\*</sup>, Jaroslav Tintera<sup>1</sup>, Jiri Zahlava<sup>1</sup>, Martin Sverepa<sup>1</sup> and Pavel Rozsival<sup>3</sup>

1JL Clinic, V Hurkach 1296/10, Prague, Czech Republic

2Czech Technical University in Prague (Faculty of Biomedical Engineering), Czech Republic

3Charles University (Faculty of Medicine in Hradec Kralove), Czech Republic

### **Abstract**

The authors report a case of binasal hemianopia in a 34-year-old female who, at the age of 22 years, underwent resection of a pinealoma located at the 3rd ventricle. Less than a year after the surgery, partial visual field losses occurred. Examination of retina, retinal nerve fiber layer (RNFL) as well as examination of the ganglion cell complex (GCC) excluded a pregeniculate lesion. Functional magnetic resonance imaging (fMRI) responses evoked by both bi- and monocular stimulation confirmed our finding of reduced activity in the visual cortex corresponding to the damage in a portion of the visual pathway.

**Keywords:** Complete binasal hemianopsia; fMRI, RNFL, GCC, tumor in the pineal region and the third cerebral ventricle

**\*Corresponding author:** Jan Lestak, MD, Ph.D., FEBO, MBA, LLA, DBA, FAOG

JL Clinic, V Hurkach 1296/10, 158 00 Prague 5, Czech Republic, E-mail: [lestak@seznam.cz](mailto:lestak@seznam.cz)

## **Introduction**

The existence of complete binasal hemianopsia has been disputed since the introduction of the first perimeters. In 1877, Foerster, one of its inventors, wrote about the relationship between the nervous system and the visual organ in the first edition of the Graef-Saemisch Compendium: “there is no binasal hemianopsia” [1]. After the introduction of automated static perimetry, the results of visual field changes became more precise and a large number of incomplete binasal hemianopsias were eliminated. In 2011, we reported on a patient with complete binasal hemianopsia [2]. Due to the fact that this report has been questioned, we decided to reopen the case, provide additional photo documentation and verify the visual field changes using functional magnetic resonance (fMRI).

## **Case study**

In November 2002, a 21-year-old nurse suddenly lost consciousness during her night shift, accompanied by limb cramps, without wetting or biting. A similar situation repeated itself in December 2002. During her examination in December 2002, she was conscious, cooperative, well-oriented, with a slight bilateral ataxia and medium-grade paleocerebellar symptomatology. The ocular finding was bilaterally normal including the perimeter.

The MRI examination of the brain carried out on December 16, 2002 revealed a hypoinvasive structure in the pineal region, sized 21x17x19 mm, slightly ventrocaudally compressing the quadrigeminal bodies, hyperintensive in the T2 weighing, with a narrow non-enhancing border; the ventricular system was narrow and the central line was without any overpressure. The pituitary stalk was localized behind the chiasm. Eye examination (January 13, 2003): eye finding within standard limits; excavation of the fundus with C/D ratio = 0.4; no signs of congestion. VA: with -3.5, -2.5 respectively = 1.0. The visual field was not examined. On January 14, 2003 a tumor was removed from the pineal region through suboccipital craniotomy. During the surgery, the tumor widely adhered and pressed against the colliculi superiores et inferiores of the upper stalk, burrowing into the caudal part of the 3rd ventricle. The tumor was partially cystic, some parts had a brittle structure while other parts had rigid bodies. The tumor was gradually sharply separated from the base, respecting its boundary against the upper stalk, and was radically removed. The histological examination established a pineocytoma.

The postoperative MRI of the brain (January 16, 2003) confirmed the radical removal of a pinealoma with no obstruction of the liquor pathways. In the postoperative period (from the 3rd postoperative day), impairment of consciousness occurred repeatedly, with no objective correlation in repeated imaging examinations (twice brain CT, once brain CT-AG). Eighteen days after surgery, the patient was released into home care. She did not appear to have any problems, apart from slight paleocerebellar symptomatology [2].

### **Outpatient follow-up**

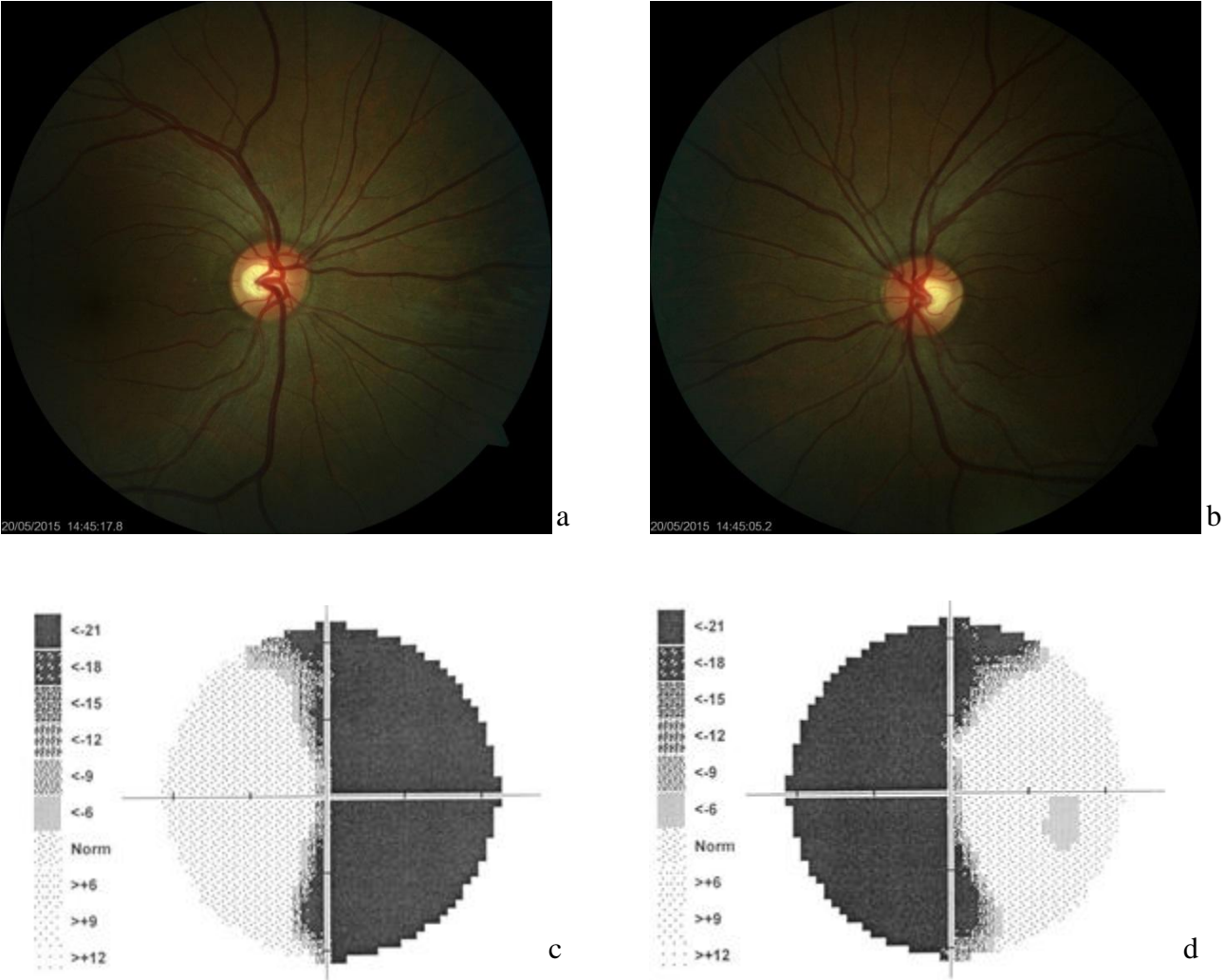
The patient's neurological state did not change until December 2003, including normal visus and provisionally examined perimeter. The ocular findings at the follow-up examination carried out by an ophthalmologist in April 2003 were normal, including the objectively performed perimeter examination. On May 27, 2003 the patient suffered a consciousness disorder (approx. 12 minutes), with clonic-tonic spasms and wandering motion of the eyes. During her hospitalization in the Neurological Department, her problem did not recur. ECG, examination of the eyegrounds and laboratory examination showed no pathological findings. CT and MRI examinations proved reparative gliosis around the aqueduct, otherwise without any other pathology. Early in December 2003, the patient experienced subjectively impaired visus. The eye examination revealed increased intraocular pressure. During her hospitalization in the Eye Clinic, the first scotomas in the nasal halves of both visual fields were found on the perimeter, further to the right.

The monthly follow-up examinations of the perimeter showed that, until the end of June 2004, the finding progressed gradually into complete binasal hemianopsia, and has persisted until now. In July 2004, the patient was examined at the lead author's clinic, where the examination of electrical retinal functions did not reveal any changes in the flash or pattern electroretinograms. The next ophthalmological examination was carried out in November 2010. Both the external and intraocular findings were normal, while the binasal hemianopsia in the perimeter still persisted. Repeated MRI examinations of the brain (annually until 2010) did not show any recurrence of the pinealoma, the reactive changes disappeared (=reactive gliosis) and the cerebral finding was normal)

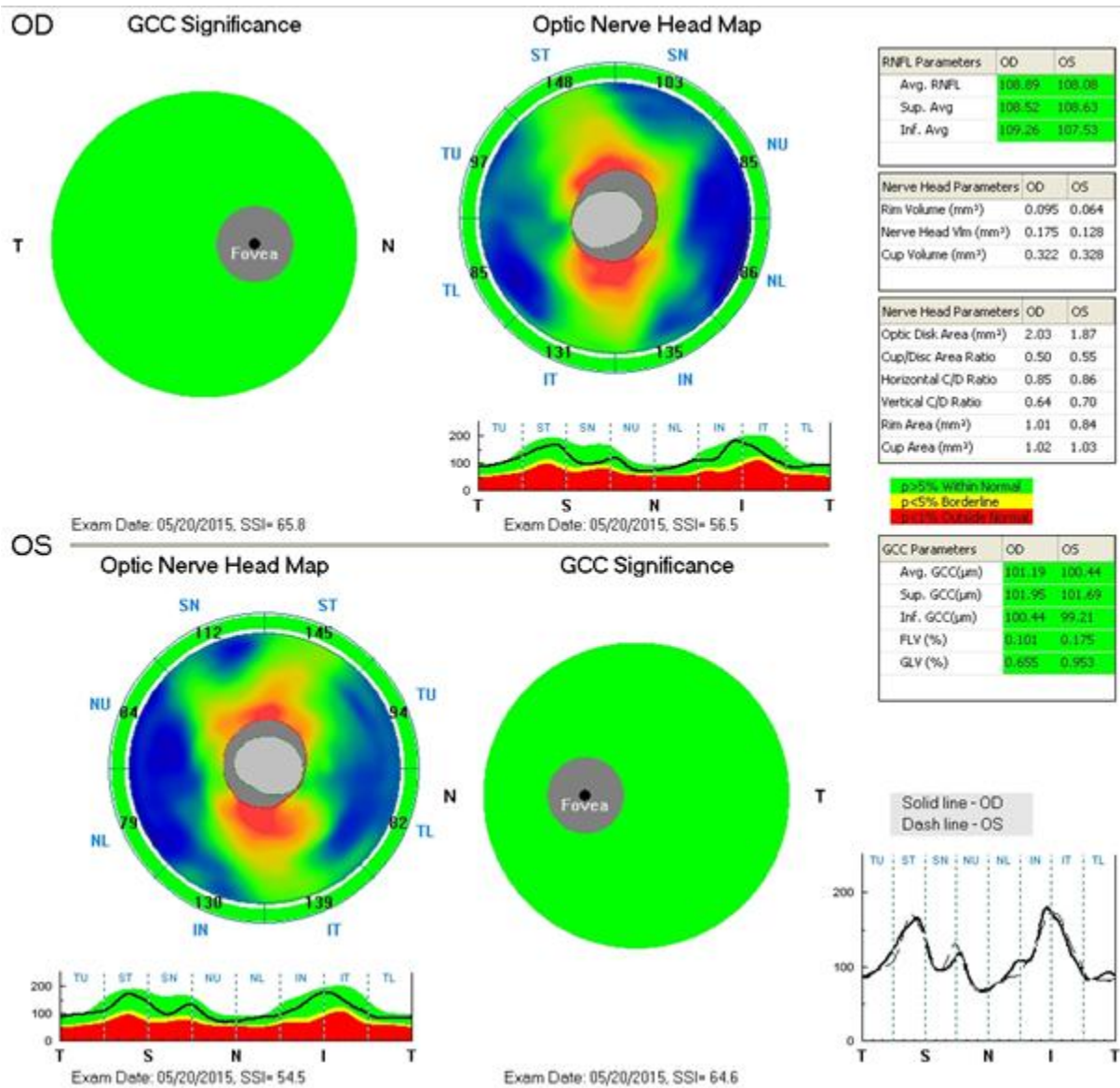
The last ophthalmological examination was performed in May 2015, with a bilaterally normal ocular finding: VA with -3.5, -2.5 respectively = 1.0; excavation of the fundus with C/D ration of 0.4; IOPs were 18 and 18 mmHg; perimeter: complete binasal hemianopsia.

This finding has remained unchanged since December 2003.

Figure 1 shows normal retina. Figure 2 shows nerve fiber layer and ganglion cell complex.



**Figure 1** Retinal imaging. Right eye a), left eye b). Visual field of the right c) and left eye d).



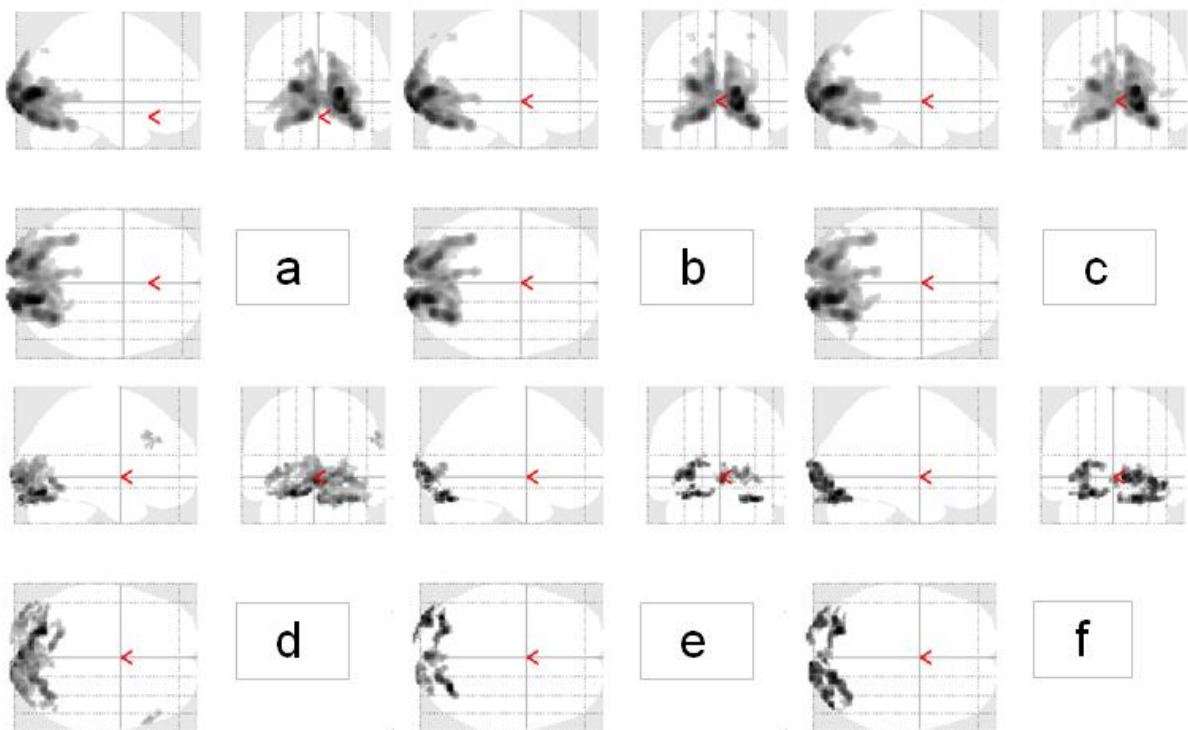
**Figure 2.** Ganglion cell complex (GCC) and optic nerve head map of the right eye (OD) – upper panel and the left eye (OS) – lower panel

### Functional MR imaging (fMRI)

Functional MRI examinations were carried out on the Philips Achieva 3T TX MR system (Philips Healthcare, Eindhoven, Netherlands) with a magnetic field strength of 3 Tesla, using the blood oxygen level dependent (BOLD) contrast. A standard 32-channel SENSE head RF coil was used for scanning. For fMRI measurements based on the BOLD technique, the gradient-echo EPI sequence was used with the following parameters: TE = 30 ms, TR = 3 s, flip angle of 90°. The measured volume contained 39 continuous slices. The voxel size measured was 2 x 2 x 2 mm (FOV = 208 x 208 mm, matrix 104 x 104, SENSE factor 1.8).

Optical stimulation was performed by a black/white checkerboard alternated with its negative image with a frequency of 2 Hz. The visual size of the black and white checkerboard was 25.8 x 16.2 degrees. The measurements consisted of a sequence of five 30-second active phase periods and five resting periods of the same length (each of 10 dynamic scans). During the resting phase, a static crosshair situated in the center of the visible field was projected for the view fixation. In total, every measurement included 100 dynamic scans and took 5 minutes. Each eye was examined by means of separate fMRI measurement (LE, RE) and also one control measurement was performed by stimulating both eyes together (LE+RE). Figure 3.

The obtained data were processed using SPM8 software and general linear model (GLM). During the pre-process, the data were motion corrected (realignment), corrected for time-shift of individual slices (slice timing), then smoothed using a Gaussian filter with FWHM of 6 x 6 x 6 mm and finally normalized into the MNI\_152 space. For statistical evaluation, the GLM with canonical hemodynamic response function (HRF) applied to the block scheme of the stimulation was used. Statistical maps were thresholded at the level of  $p = 0.05$  with FWE correction for multiple observations.



**Figure 3** shows typical activation in healthy volunteer (upper row) and patient with binasal hemianopsia (bottom row) on a), d) bilateral stimulation, b), e) stimulation of the right eye and c), f) stimulation of the left eye.



eye	voxels		
	RH+LH	RH	LH
RE+LE	9 410	3 960	3 950
RE	8 740	3 920	3 680
LE	10 100	4 200	4 140

**Table 1** shows the number of significantly activated voxels ( $p=0.05$  with FWE correction) in the healthy volunteer occipital lobe of the right hemisphere (RH), left hemisphere (LH) and total brain activation (RH+LH). The activation extent is shown for bilateral stimulation (RE+LE) and separate stimulation of the right eye (RE) and left eye (LE).

eye	voxels		
	RH+LH	RH	LH
RE+LE	3 470	1 570	1 460
RE	1 040	440	600
LE	1 840	800	680

**Table 2** shows the same results as Table 1, but in the patient

## Discussion

Binasal hemianopsia is a condition structurally related to uncrossed optic fibers. This means that, during stimulation of either of the eyes, the signal alteration should occur in the ipsilateral occipital hemisphere.

Table 2 shows stimulation of the right eye, resulting in lower activation (voxels) in the right hemisphere when compared to the left hemisphere (440 vs. 600). During the stimulation of the left eye, the finding is reversed (800 vs. 680). There was no significant difference between the hemispheres in healthy individuals during identical monocular stimulation (2.2 %;  $p=0.85$ ) [3].

Due to the extent of the damage involving not only nasal but partly also temporal visual fields, the activity of the visual cortex during bi- as well as monocular stimulation in our patient is markedly lower.

The exact localization and development process of the lesion remain elusive. If the binasal hemianopsia had a structural correlate in the peripheral portion of the visual pathway (pregeniculate), pathology would be found at the optic discs, in the nerve fiber layer of the retinal ganglion cells, as well as in the ganglion cells themselves. In our patient, no such pathologies were observed. It is feasible, however, to assume a central (suprageniculate) localization of the lesion.

The decreased activity of the visual cortex supports the presence of a structural, rather than a functional correlate of the binasal changes.

### **Conclusion:**

By fMRI, we were able to confirm a structural background for the binasal hemianopsia in our patient, although we can only speculate on the detailed localization of the lesion.

The study protocol was approved by the local Ethics Committee and the study was performed in accordance with Good Clinical Practice and the Declaration of Helsinki.

### **Acknowledgments**

Grant support, research funding and proprietary interest is none, and presentation at meeting is also none.

### **Conflict of interest statement**

The authors state that there are no conflicts of interest regarding the publication of this article.

### **Reference**

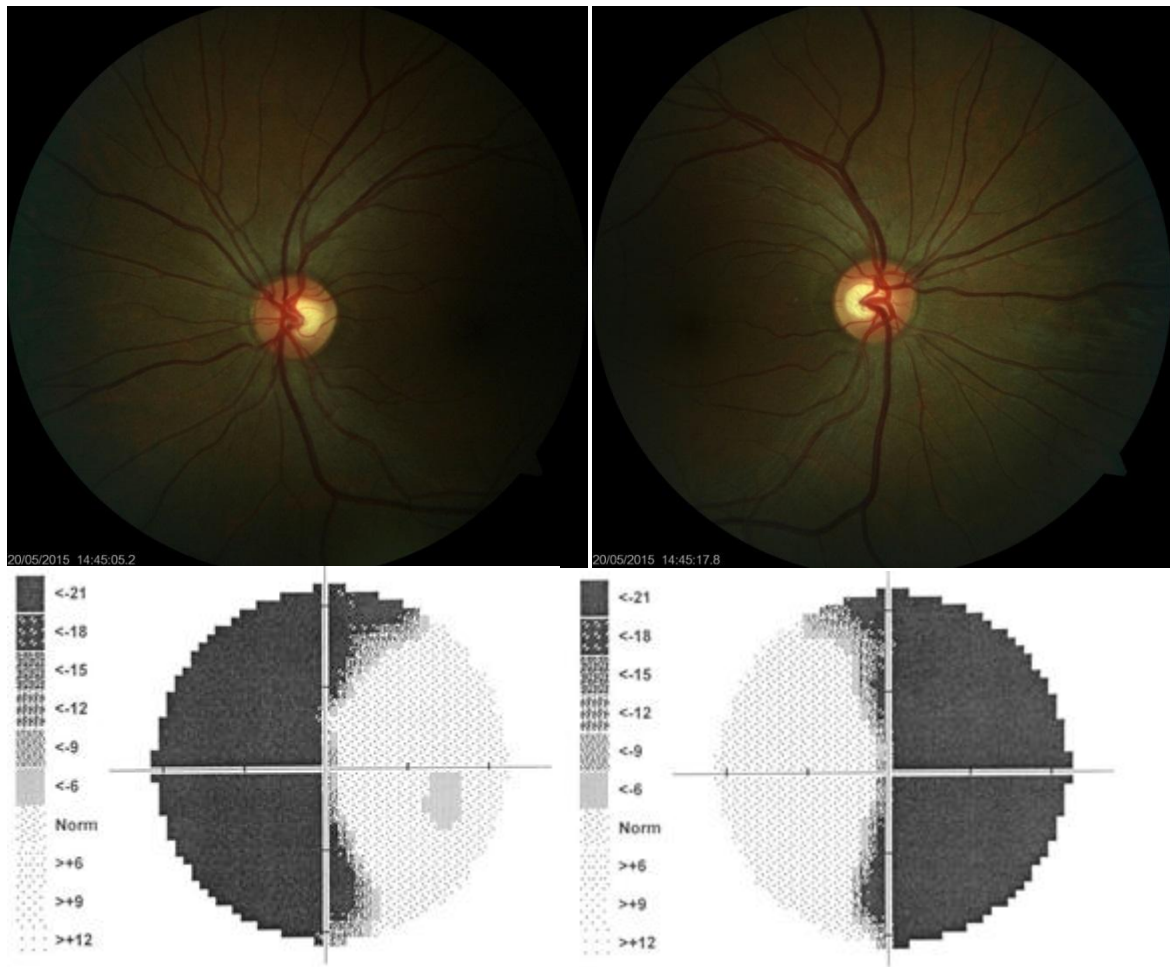
1. Kurz J (1955) Oftalmo-neurologická diagnostika. Státní zdravotnické nakladatelství, Praha, p. 674.
2. Lestak J, Skuci I, Ricarova R, Choc M and Kastner J (2011) Complete Binasal Hemianopsia. J Clin Exp Ophthalmol, S:5 <http://dx.doi.org/10.4172/2155-9570.S5-002>
3. Lestak J, Tintera J, Rozsival P (2014) FMRI and ocular dominance. IJSR – International Journal of Scientific Research, 3: 293–296.

eye	voxels		
	RH+LH	RH	LH
RE+LE	9 410	3 960	3 950
RE	8 740	3 920	3 680
LE	10 100	4 200	4 140

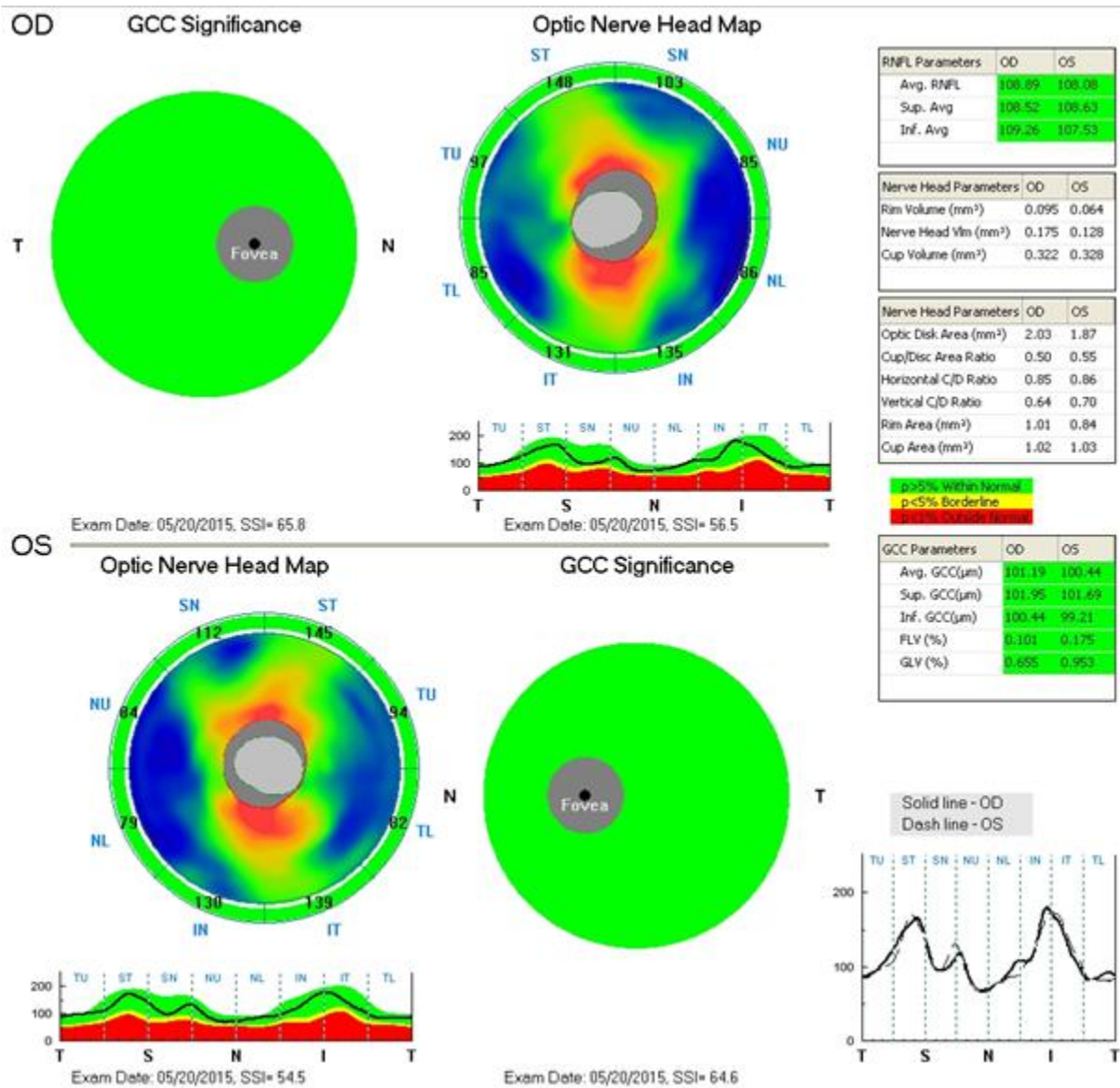
**Table 1** shows the number of significantly activated voxels ( $p=0.05$  with FWE correction) in the healthy volunteer occipital lobe of the right hemisphere (RH), left hemisphere (LH) and total brain activation (RH+LH). The activation extent is shown for bilateral stimulation (RE+LE) and separate stimulation of the right eye (RE) and left eye (LE).

eye	voxels		
	RH+LH	RH	LH
RE+LE	3 470	1 570	1 460
RE	1 040	440	600
LE	1 840	800	680


**Table 2** shows the same results as Table 1, but in the patient



**Figure 1** Retinal imaging. Right eye a), left eye b). Visual field of the right c) and left eye d).



**Figure 2.** Ganglion cell complex (GCC) and optic nerve head map of the right eye (OD) – upper panel and the left eye (OS) – lower panel



**Figure 3** shows typical activation in healthy volunteer (upper row) and patient with binasal hemianopsia (bottom row) on a), d) bilateral stimulation, b), e) stimulation of the right eye and c), f) stimulation of the left eye.

## **Functional magnetic resonance in binasal hemianopsia.**

Jan Lestak<sup>1,2,3\*</sup>, Jaroslav Tintera<sup>1</sup>, Jiri Zahlava<sup>1</sup>, Martin Sverepa<sup>1</sup> and Pavel Rozsival<sup>3</sup>

1JL Clinic, V Hurkach 1296/10, Prague, Czech Republic

2Czech Technical University in Prague (Faculty of Biomedical Engineering), Czech Republic

3Charles University (Faculty of Medicine in Hradec Kralove), Czech Republic

### **Abstract**

The authors report a case of binasal hemianopia in a 34-year-old female who, at the age of 22 years, underwent resection of a pinealoma located at the 3rd ventricle. Less than a year after the surgery, partial visual field losses occurred. Examination of retina, retinal nerve fiber layer (RNFL) as well as examination of the ganglion cell complex (GCC) excluded a pregeniculate lesion. Functional magnetic resonance imaging (fMRI) responses evoked by both bi- and monocular stimulation confirmed our finding of reduced activity in the visual cortex corresponding to the damage in a portion of the visual pathway.

**Keywords:** Complete binasal hemianopsia; fMRI, RNFL, GCC, tumor in the pineal region and the third cerebral ventricle

**\*Corresponding author:** Jan Lestak, MD, Ph.D., FEBO, MBA, LLA, DBA, FAOG

JL Clinic, V Hurkach 1296/10, 158 00 Prague 5, Czech Republic, E-mail: [lestak@seznam.cz](mailto:lestak@seznam.cz)



## **Introduction**

The existence of complete binasal hemianopsia has been disputed since the introduction of the first perimeters. In 1877, Foerster, one of its inventors, wrote about the relationship between the nervous system and the visual organ in the first edition of the Graef-Saemisch Compendium: “there is no binasal hemianopsia” [1]. After the introduction of automated static perimetry, the results of visual field changes became more precise and a large number of incomplete binasal hemianopsias were eliminated. In 2011, we reported on a patient with complete binasal hemianopsia [2]. Due to the fact that this report has been questioned, we decided to reopen the case, provide additional photo documentation and verify the visual field changes using functional magnetic resonance (fMRI). **We want to prove that the change in activation laterality when comparing the visual stimulation of the right and left eye separately can be detected by fMRI and support results of the standard examination of the patient with binasal hemianopsia. Therefore, we formulate the following hypothesis: A patient with binasal hemianopsia has weaker activation in the right occipital lobe during stimulation of the right eye and weaker activation in the left occipital lobe during stimulation of the left eye. Additionally, the patient can have weaker activation generally in both hemispheres compared to healthy controls. This fact leads to evaluate lateralization index (LI) of the activation rather than to compare only strength of the activation expressed in number of statistically significant voxels.**

## **Material and methods**

### **Patient history**

In November 2002, a 21-year-old nurse suddenly lost consciousness during her night shift, accompanied by limb cramps, without wetting or biting. A similar situation repeated itself in December 2002. During her examination in December 2002, she was conscious, cooperative, well-oriented, with a slight bilateral ataxia and medium-grade paleocerebellar symptomatology. The ocular finding was bilaterally normal including the perimeter.

The MRI examination of the brain carried out on December 16, 2002 revealed a hypoinvasive structure in the pineal region, sized 21x17x19 mm, slightly ventrocaudally compressing the quadrigeminal bodies, hyperintensive in the T2 weighing, with a narrow non-enhancing

border; the ventricular system was narrow and the central line was without any overpressure. The pituitary stalk was localized behind the chiasm. On January 14, 2003 a tumor was removed from the pineal region through suboccipital craniotomy. The tumor was gradually sharply separated from the base, respecting its boundary against the upper stalk, and was radically removed. The histological examination established a pineocytoma. The postoperative MRI of the brain (January 16, 2003) confirmed the radical removal of a pinealoma with no obstruction of the liquor pathways. Eighteen days after surgery, the patient was released into home care. She did not appear to have any problems, apart from slight paleocerebellar symptomatology [2].

### **Outpatient follow-up**

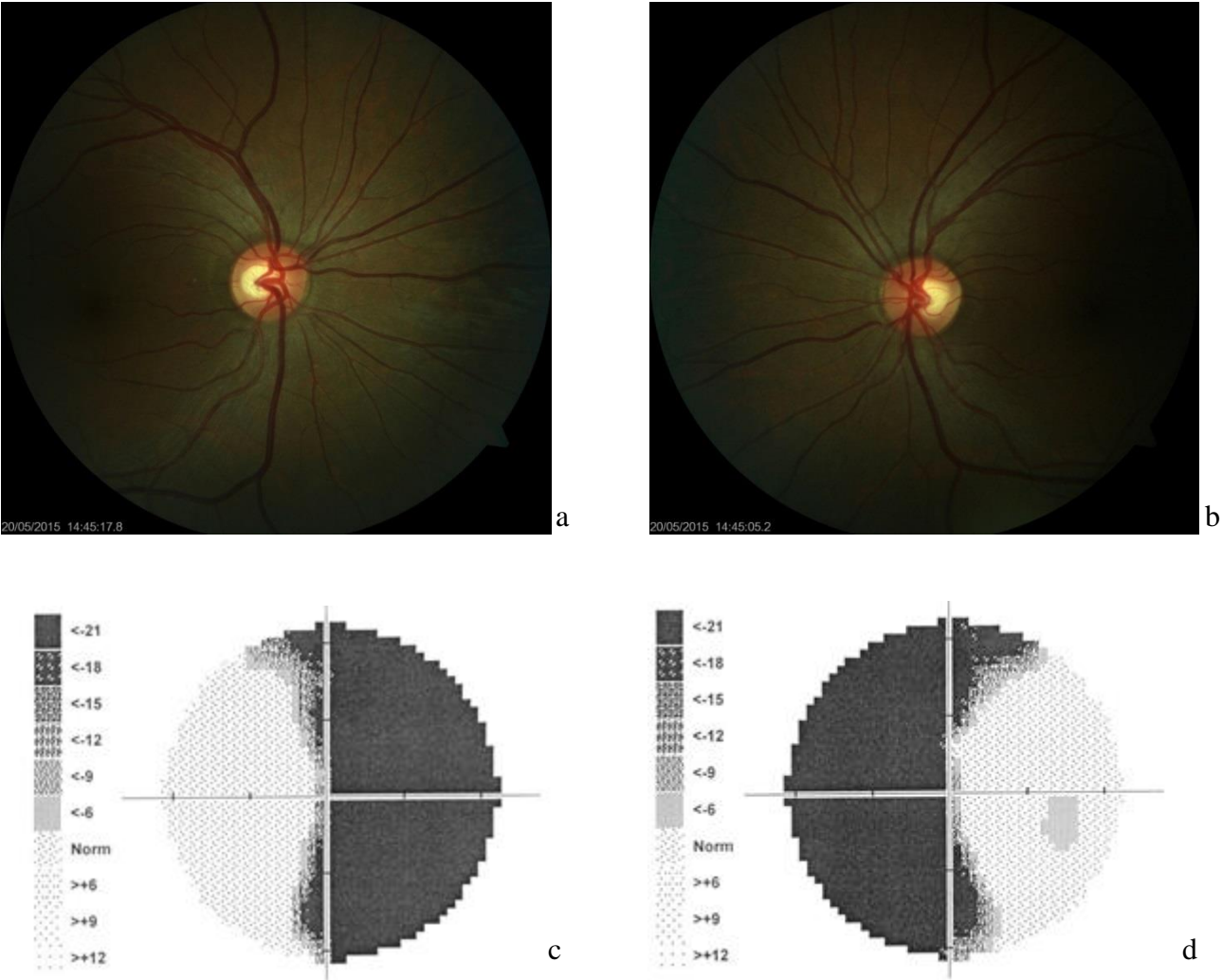
The patient's neurological state did not change until December 2003, including normal visus and provisionally examined perimeter. The ocular findings at the follow-up examination carried out by an ophthalmologist in April 2003 were normal, including the objectively performed perimeter examination. On May 27, 2003 the patient suffered a consciousness disorder (approx. 12 minutes), with clonic-tonic spasms and wandering motion of the eyes. During her hospitalization in the Neurological Department, her problem did not recur. ECG, examination of the eyegrounds and laboratory examination showed no pathological findings. CT and MRI examinations proved reparative gliosis around the aqueduct, otherwise without any other pathology. Early in December 2003, the patient experienced subjectively impaired visus. The eye examination revealed increased intraocular pressure. During her hospitalization in the Eye Clinic, the first scotomas in the nasal halves of both visual fields were found on the perimeter, further to the right.

The monthly follow-up examinations of the perimeter showed that, until the end of June 2004, the finding progressed gradually into complete binasal hemianopsia, and has persisted until now. In July 2004, the patient was examined at the lead author's clinic, where the examination of electrical retinal functions did not reveal any changes in the flash or pattern electroretinograms. The next ophthalmological examination was carried out in November 2010. Both the external and intraocular findings were normal, while the binasal hemianopsia in the perimeter still persisted. Repeated MRI examinations of the brain (annually until 2010) did not show any recurrence of the pinealoma, the reactive changes disappeared (=reactive gliosis) and the cerebral finding was normal.

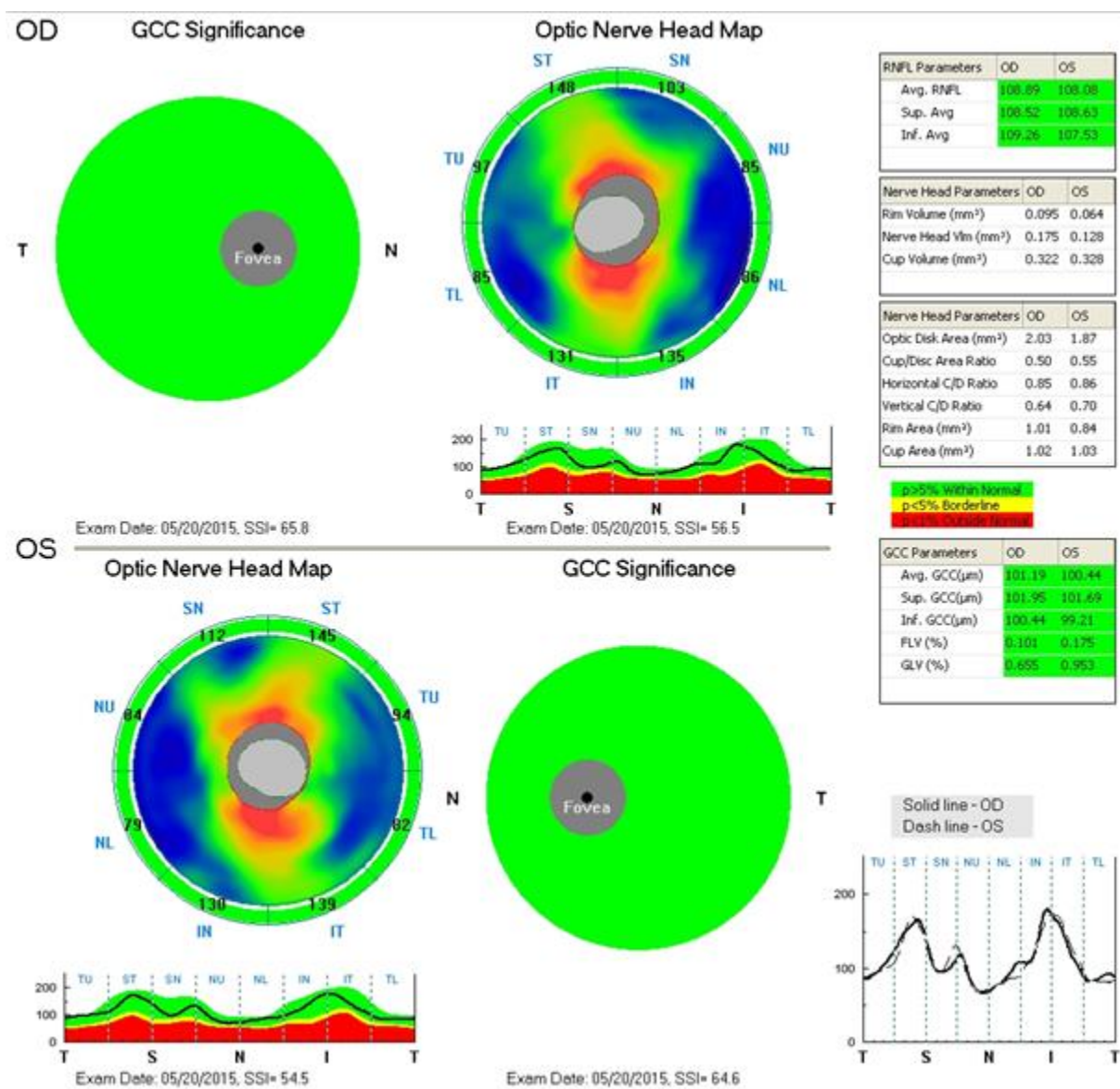
The last ophthalmological examination was performed in May 2015, with a bilaterally normal ocular finding: VA with -3.5, -2.5 respectively = 1.0; excavation of the fundus with C/D ratio of 0.4; IOPs were 18 and 18 mmHg; perimeter: complete binasal hemianopsia.

This finding has remained unchanged since December 2003.

Figure 1 shows normal retina. Figure 2 shows nerve fiber layer and ganglion cell complex.



**Figure 1** Retinal imaging. Right eye a), left eye b). Visual field of the right c) and left eye d).



**Figure 2.** Ganglion cell complex (GCC) and optic nerve head map of the right eye (OD) – upper panel and the left eye (OS) – lower panel

### Control group

Control group consists of 6 healthy female subjects (average age of 35 years). All subjects had complete ophthalmologic examination excluding any pathology in visual field and attended the fMRI examination with identical protocol as the patient.

### Functional MR imaging (fMRI)

Functional MRI examinations were carried out on the Philips Achieva 3T TX MR system (Philips Healthcare, Eindhoven, Netherlands) with a magnetic field strength of 3 Tesla, using

the blood oxygen level dependent (BOLD) contrast. A standard 32-channel SENSE head RF coil was used for scanning. For fMRI measurements based on the BOLD technique, the gradient-echo EPI sequence was used with the following parameters: TE = 30 ms, TR = 3 s, flip angle of 90°. The measured volume contained 39 continuous slices. The voxel size measured was 2 x 2 x 2 mm (FOV = 208 x 208 mm, matrix 104 x 104, SENSE factor 1.8). Optical stimulation was performed by a black/white checkerboard alternated with its negative image with a frequency of 2 Hz. The visual size of the black and white checkerboard was 25.8 x 16.2 degrees. The measurements consisted of a sequence of five 30-second active phase periods and five resting periods of the same length (each of 10 dynamic scans). During the resting phase, a static crosshair situated in the center of the visible field was projected for the view fixation. In total, every measurement included 100 dynamic scans and took 5 minutes. Each eye was examined by means of separate fMRI measurement (LE, RE) and also one control measurement was performed by stimulating both eyes together (LE+RE). Figure 3.

The obtained data were processed using SPM8 software and general linear model (GLM). During the pre-process, the data were motion corrected (realignment), corrected for time-shift of individual slices (slice timing), then smoothed using a Gaussian filter with FWHM of 6 x 6 x 6 mm and finally normalized into the MNI\_152 space. For statistical evaluation, the GLM with canonical hemodynamic response function (HRF) applied to the block scheme of the stimulation was used. Statistical maps were thresholded at the level of  $p = 0.05$  with FWE correction for multiple observations. **The extent of the activation (number of statistically significant voxels) is strongly dependent on the choice of the statistical threshold. In case of very different strength of the activation the evaluation of the activation laterality can be challenging. This is especially valid when comparing a patient (with general weaker activation) with healthy controls. Therefore, a threshold independent method to evaluate lateralization of the fMRI activation using bootstrap introduced by Wilke et al. was used and the extent of activations in occipital lobe of both hemispheres is expressed as lateralization index (LI) which is a ration defined by the relation**

$$LI = (A_{LH} - A_{RH}) / (A_{LH} + A_{RH})$$

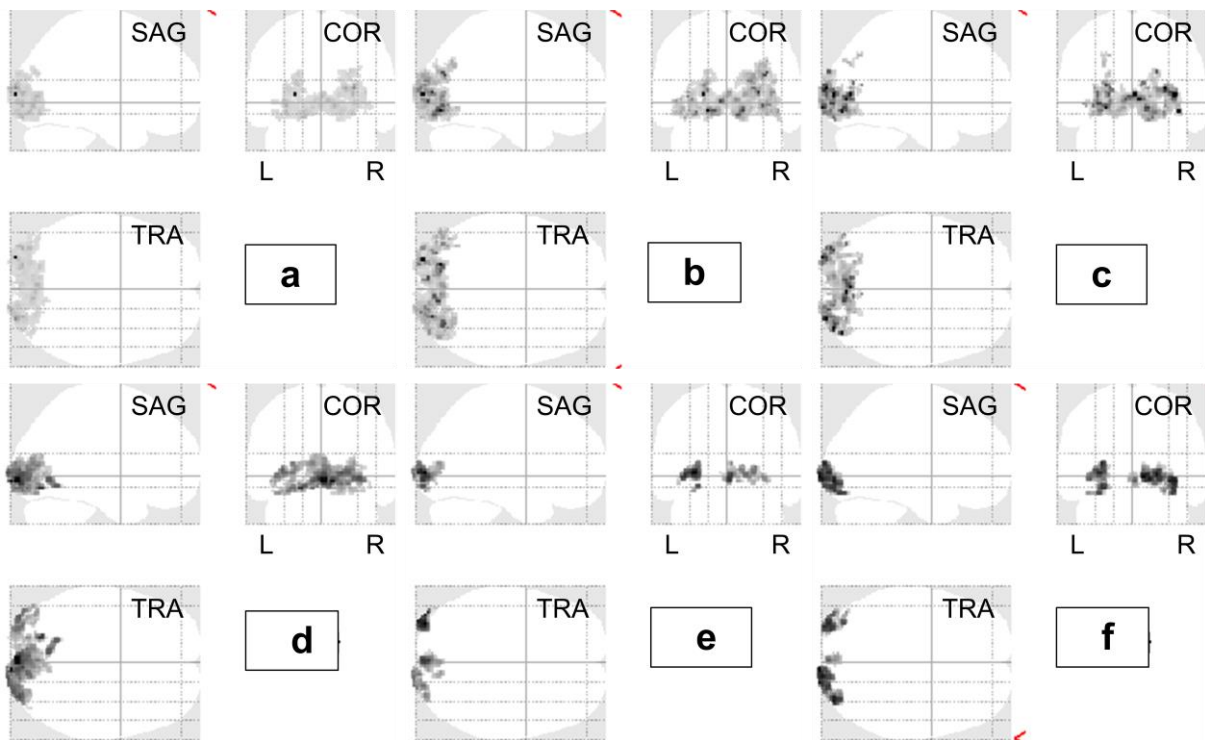
where  $A_{LH}$ ,  $A_{RH}$  is the number of activated voxels in the left or right hemisphere resp. Complete left side activation is represented by  $LI = 1$  while  $LI = -1$  means exclusively right side activation.

Lateralization index was calculated by bootstrap method in SPM toolbox [4, 5]. Default parameters of the LI toolbox were used for the calculation: sub-sample size  $k=25\%$ , minimum

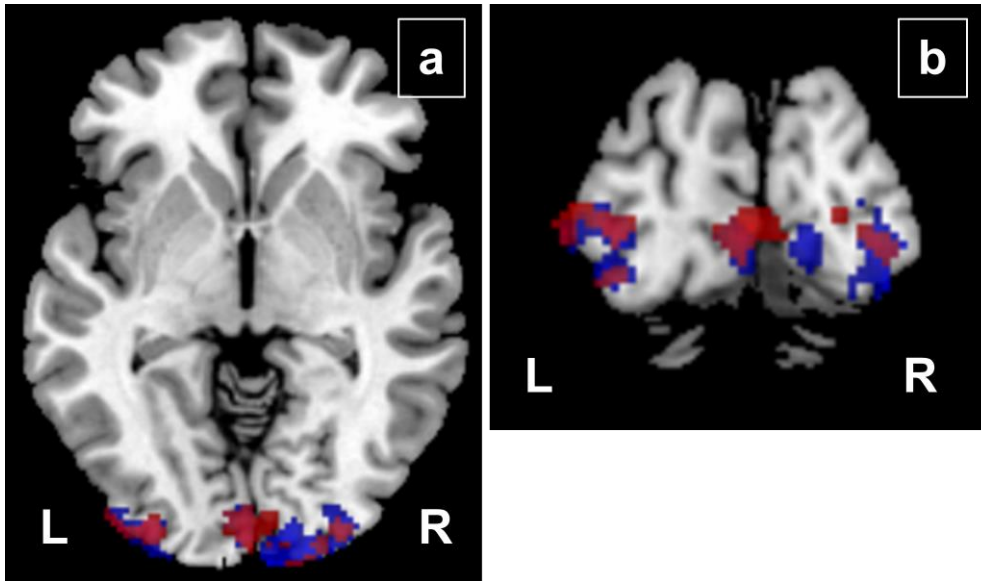
sample size 5, maximum sample size 10 000 and only voxels from occipital lobes were used by masking.

## Results

The comparison of activations between the group of 6 healthy female volunteers (a-c) and patient with binasal hemianopsia (d-e) is shown in fig. 3. In average, healthy subjects had more extensively activated visual cortex then the patient. Moreover, difference in the laterality of the activation can be seen also in fig. 4 where red color represents the response on the stimulation of the right eye and blue color the activation during left eye stimulation. Decrease of the activation in the right occipital lobe as a response to right eye stimulation as well as a decrease in the left occipital lobe during left eye stimulation is visible.



**Figure 3** shows fMRI activation (sagittal, coronal and transversal maximum intensity projection) in group of healthy volunteers (upper row) and patient with binasal hemianopsia (bottom row) on a), d) bilateral stimulation, b), e) stimulation of the right eye and c), f) stimulation of the left eye.



**Figure 4** demonstrates possible shift of the activation. Red color shows the activation during right eye stimulation and blue color during left eye stimulation. In case of left eye, activations are stronger in right hemisphere and by stimulating right eye more activations are located in left side.

More quantitative approach using the quantification of LI is shown in Table 1. Results of LI during bilateral, right and left eye stimulation are presented for all 6 healthy controls and for the patient with binasal hemianopsia. All volunteers have either left side activation dominance (LI is positive) or right side dominance (negative LI) for both eyes but the patient has positive LI = 0.18 for right eye stimulation (decreased right hemisphere activation) and negative LI = -0.16 for left eye stimulation (decreased left hemisphere activation).

subject	LI bilateral stimulation	LI right eye stimulation	LI left eye stimulation
control 1	0.32	0.29	0.41
control 2	-0.21	-0.47	-0.08
control 3	-0.29	-0.26	-0.14
control 4	0.30	0.25	0.38
control 5	0.31	0.30	0.20
control 6	-0.15	-0.01	-0.09
patient BH	0.16	0.18	-0.16

**Table 1** shows the activation laterality expressed as a lateralization index (LI) for 6 healthy female volunteers and patient with binasal hemianopsia during bilateral stimulation and separate stimulation of the right or left eye.

## Discussion

Binasal hemianopsia is a condition structurally related to uncrossed optic fibers. This means that, during stimulation of either of the eyes, the signal alteration should occur in the ipsilateral occipital hemisphere.

Due to the extent of the damage involving not only nasal but partly also temporal visual fields, the activity of the visual cortex during bi- as well as monocular stimulation in our patient is markedly lower.

The exact localization and development process of the lesion remain elusive. If the binasal hemianopsia had a structural correlate in the peripheral portion of the visual pathway (pregeniculate), pathology would be found at the optic discs, in the nerve fiber layer of the retinal ganglion cells, as well as in the ganglion cells themselves. In our patient, no such pathologies were observed. It is feasible, however, to assume a central (supragenicolate) localization of the lesion.

The decreased activity of the visual cortex supports the presence of a structural, rather than a functional correlate of the binasal changes.

### **Conclusion:**

By fMRI, we were able to confirm a structural background for the binasal hemianopsia in our patient, although we can only speculate on the detailed localization of the lesion.

The study protocol was approved by the local Ethics Committee and the study was performed in accordance with Good Clinical Practice and the Declaration of Helsinki.

### **Acknowledgments**

Grant support, research funding and proprietary interest is none, and presentation at meeting is also none.

### **Conflict of interest statement**

The authors state that there are no conflicts of interest regarding the publication of this article.

### **Reference**

1. Kurz J (1955) Oftalmo-neurologická diagnostika. Státní zdravotnické nakladatelství, Praha, p. 674.



2. Lestak J, Skuci I, Ricarova R, Choc M and Kastner J (2011) Complete Binasal Hemianopsia. J Clin Experiment Ophthalmol, S:5 <http://dx.doi.org/10.4172/2155-9570.S5-002>

3. Lestak J, Tintera J, Rozsival P (2014) FMRI and ocular dominance. IJSR – International Journal of Scientific Research, 3: 293–296.

4. Wilke M, Schmithorst VJ (2006) A combined bootstrap/histogram analysis approach for computing a lateralization index from neuroimaging data. Neuroimage, 33: 522-530.

5. Wilke M, Lidzba K (2007) LI-tool: A new toolbox to assess lateralization in functional MR-data. Journal of Neuroscience Methods, 163: 128-136.

The examination of the visual field belongs to subjective ophthalmologic examinations. The aim of our work was to objectively classify changes in visual field using fMRI. Decreased activation detected by fMRI can be caused by means of the decreased action potentials incoming to the visual cortex or by damage of the visual center itself and/or combination of both. In this work we do not evaluate the proportion of single reasons but the only change of activation in both hemispheres itself (lateralization of the activation).