

OMICS PUBLISHING GROUP/Clinical

Diagnosics and treatment of polymicrobial keratitis and endophthalmitis - case report --Manuscript Draft--

Manuscript Number:	CLINICALGROUP-13-313R2
Full Title:	Diagnosics and treatment of polymicrobial keratitis and endophthalmitis - case report
Short Title:	Polymicrobial keratitis and endophthalmitis - case report
Article Type:	Case Report
Section/Category:	Journal of Clinical & Cellular Immunology
Keywords:	keratitis; endophthalmitis; coagulase-negative Staphylococcus; Fusarium; diagnosics; treatment
Corresponding Author:	Jan Lešták CZECH REPUBLIC
Corresponding Author Secondary Information:	
Corresponding Author's Institution:	
Corresponding Author's Secondary Institution:	
First Author:	Nada Jiraskova, MD, PhD
First Author Secondary Information:	
Order of Authors:	Nada Jiraskova, MD, PhD Vladimir Buchta Dimitar Hadži Nikolov Marcela Vejsová Pavel Rozsival Jan Lešták
Order of Authors Secondary Information:	
Manuscript Region of Origin:	CZECH REPUBLIC
Abstract:	<p>Purpose: To describe a case of polymicrobial keratitis and endophthalmitis successfully treated with topical and systemic antibacterial and antifungal agents, collagen cross-linking (CXL) and penetrating keratoplasty.</p> <p>Methods: Case report</p> <p>Results: A 59-year-old woman presented with a corneal ulcer. Multiple samplings of the corneal lesion were used for microbiological investigations by standard protocol that repeatedly revealed coagulase-negative Staphylococcus sp. (CoNS); mycotic tests were negative. She was treated with topical and systemic antibiotics and an emergency therapeutic keratoplasty was performed. Four months later she was readmitted for ulcerative keratitis and endophthalmitis. Corneal cytology and aqueous humor cultures showed a Fusarium species, CoNS and Bacillus species. She was treated with topical and systemic voriconazole, antibacterials, and the corneal cross-linking (CXL) procedure. Complete resolution of the infection was observed but a large vascular leucoma developed. A penetrating keratoplasty and anterior segment reconstruction surgery with very good results were performed seven months later.</p> <p>Conclusions: Voriconazole, antibacterial antibiotics and CXL were effective in the management of a severe polymicrobial corneal ulcer progressing to endophthalmitis with no side-effects observed.</p>
Suggested Reviewers:	
Opposed Reviewers:	

Response to Reviewers:

All the points have been revised according to your suggestions.

Diagnostics and treatment of polymicrobial keratitis and endophthalmitis – case report

Nada Jirasková^{1,6}, MD, PhD, Professor, Senior Consultant Ophthalmologist

Vladimir Buchta^{2,6}, PhD, Assoc. Professor, Head of the Department

Dimitar Hadži Nikolov^{3,6}, MD, PhD, Senior Consultant Pathologist

Marcela Vejsová^{2,6}, PhD, Microbiologist

Pavel Rozsival^{1,6}, MD, PhD, FEBO, Professor, Head of the Department

Jan Lešták^{4,5,6}, MD, PhD, FEBO, Head of the Clinic

1Department of Ophthalmology, University Hospital and Charles University Medical Faculty, Hradec Králové, Czech Republic

2Department of Clinical Microbiology, University Hospital and Charles University Medical Faculty, Hradec Králové, Czech Republic

3Fingerland Department of Pathology, University Hospital and Charles University Medical Faculty, Hradec Králové, Czech Republic

4JL Clinic, V Hurkách 1296/10, Prague, Czech Republic

5Czech Technical University in Prague (Faculty of Biomedical Engineering), Czech Republic

6Charles University (Faculty of Medicine in Hradec Kralove), Czech Republic

Corresponding author: Jan Lešták, MD, PhD, FEBO, JL Clinic, V Hůrkách 1296/10, Prague, Czech Republic, e-mail: lestak@seznam.cz

None of the authors has a financial or proprietary interest in any product mentioned.

Supported by Charles University in Prague - Programme P37/07 (PRVOUK) and SVV 266902.

Abstract

Purpose: To describe a case of polymicrobial keratitis and endophthalmitis successfully treated with topical and systemic antibacterial and antifungal agents, collagen cross-linking (CXL) and penetrating keratoplasty.

Methods: Case report

Results: A 59-year-old woman presented with a corneal ulcer. Multiple samplings of the corneal lesion were used for microbiological investigations by standard protocol that repeatedly revealed coagulase–negative *Staphylococcus* sp. (CoNS); mycotic tests were negative. She was treated with topical and systemic antibiotics and an emergency therapeutic keratoplasty was performed. Four months later she was readmitted for ulcerative keratitis and endophthalmitis. ~~Corneal cytology and aqueous humor cultures~~ Laboratory work up on corneal scraping and aqueous humor cultures showed a *Fusarium* species, CoNS and *Bacillus* species. She was treated with topical and systemic voriconazole, antibacterials, and the corneal cross-linking (CXL) procedure. Complete resolution of the infection was observed but a large vascular leucoma developed. A penetrating keratoplasty and anterior segment reconstruction surgery with very good results were performed seven months later.

Conclusions: Voriconazole, antibacterial antibiotics and CXL were effective in the management of a severe polymicrobial corneal ulcer progressing to endophthalmitis with no side-effects observed.

Key words: keratitis, endophthalmitis, coagulase–negative *Staphylococcus*, *Fusarium*, diagnostics, treatment

Introduction:

Corneal infections can cause severe ocular damage and remain an important cause of blindness that requires anti-microbial therapy or suitable surgical treatment to preserve useful vision. Fungal keratitis and endophthalmitis are relatively rare in temperate climates, but they nevertheless have potentially devastating consequences. In 2006 the US Centers for Disease Control (CDC) reported an outbreak of at least 130 confirmed cases of *Fusarium* keratitis among contact lens wearers in 26 states [1]. The CDC's case-control investigation found an association between the fungal infections and use of a particular contact lens solution, which was subsequently withdrawn from the global market.

Corneal trauma associated with implantation of organic matter contaminated with fungal spores is the main predisposing factor for keratomycosis; other factors are contact lens use and previous ocular surgery [2]. It has also been suggested that the frequent use of corticosteroids during the past four decades has also contributed to the increased incidence of fungal infection of the cornea. Corticosteroids appear to reduce the resistance of the cornea to fungal agents and support the development of existing fungal corneal infections.

Fusarium species are fast-growing ubiquitous hyalohyphomycetes that are present in soil, water, and plants. They have been reported to be the most frequent cause of fungal keratitis, causing up to 32% of these infections [3]. *Fusarium* infection, which normally manifests as an anterior stromal keratitis, may invade rapidly into the deep layers of the cornea and penetrate Descemet's membrane, resulting in endophthalmitis [4].

We present a case of polymicrobial keratitis and endophthalmitis in which *Fusarium* species and coagulase-negative *Staphylococcus* sp. (CoNS) were implicated as causative agents. The combination of systemic and topical voriconazole and broad spectrum antibiotics with corneal cross-linking (CXL) procedure resulted in resolution of the infection. A successful penetrating

keratoplasty and anterior segment reconstruction surgery were performed seven months later and the patient's vision stabilized at 0.4.

Case report

A fifty-nine-year old woman was referred to the Department of Ophthalmology, University Hospital and Charles University Medical Faculty, Hradec Kralove, Czech Republic in November 2011 due to corneal ulcer in her right eye, which had developed during a period of 1 week. She reported that she suffered from rheumatoid arthritis, and also that she had been receiving treatment for sicca syndrome with artificial tears for 3 years. She did not wear contact lenses, but she was an agricultural worker and could not exclude "a small eye injury". The corneal lesion was treated by a local ophthalmologist with topical tobramycin 0.3% eye drops and dexamethasone 0.1% eye drops every two hours without improvement. The visual acuity of the affected eye was 0.3. The conjunctiva showed severe deep injection, and a paracentral 2.5 mm round corneal ulcer with an infiltrate nasal to the visual axis ~~was present~~ with mild anterior chamber reaction ~~were present~~ (Fig.1). She was admitted to hospital and ~~corneal cytology and aqueoocentesis~~scraping for corneal cytology and paracentesis were performed for Gram stain and microbiological cultivation (blood agar, chocolate agar, McConkey agar, liver broth and Sabouraud agar). Microscopy was negative and repeat culture results revealed coagulase-negative *Staphylococcus* sp. (CoNS) but no fungal or anaerobic microorganisms. According to the antibiotic susceptibility profile, therapy was introduced with tobramycin 0.3% hourly and moxifloxacin eye drops 5 times a day topically, together with vancomycin 1g twice a day and ceftazidime 1g twice a day intravenously. Topical mydriatics and cycloplegic drops were also used. Despite initially doing well under this therapy, 7 days later the infiltrate increased in size and corneal thinning progressed (Fig.2). A therapeutic penetrating keratoplasty for progression of inflammation and perforation of the ulcer was performed 2 weeks after presentation (Fig.3). The entire corneal abscess was

excised and a corneal graft (7.25 mm diameter) was sutured into the normal corneal tissue.

Investigation of the anterior chamber isolate identified the presence of *Staphylococcus hominis*. The excised cornea was processed for histology and staining. Histological examination by hematoxylin-eosin stain revealed a purulent abscess in the substantia propria under the corneal epithelium (Fig.4). Histochemical Gram stain was negative for detection of bacteria. Special Grocott's silver stain failed to confirm the presence of fungal organisms.

The postoperative course was without complication: systemic antibiotic treatment was discontinued and topical steroids (dexamethasone 0.1 % eye drops) every 2 hours were added to topical antibiotic treatment. Four months after the first hospitalization, the patient presented with severe ulcerative keratitis and endophthalmitis (Fig 5). Microbiological evaluation of

corneal ~~eytology~~scrapings and aqueous humor revealed *Fusarium* species, ~~corneal-eytology~~ CoNS and *Bacillus* species. Voriconazole intravenously (200 mg twice a day) and topically (1% voriconazole eye drop solution at hourly intervals) was applied to obtain high drug levels at the site of infection. Broad spectrum antibiotics were also used: tobramycin 0.3% eye drops hourly and levofloxacin 5mg/ml eye drops five times per day topically, and vancomycin 1g twice a day and ceftazidime 1g twice a day intravenously. Topical mydriatics and cycloplegic drops were administered 3 times a day. Corneal cross-linking (CXL) procedure was

performed on day 7. Because the patient was doing well under this therapy, after day 12 of treatment with intravenous voriconazole and antibiotics, the treatment was changed to

voriconazole tablets 200mg and ciprofloxacin tablets 500mg every ~~12~~ twelve hours. The frequency of topically applied 1% voriconazole eye drops was decreased to 6 times a day.

This regimen was continued to complete a 1-month course, and during the whole period was well tolerated, with no apparent systemic or topical adverse effects. The infection and inflammation resolved over the next 4 weeks (Fig.6). Visual acuity was light perception due to dense vascular corneal leucoma and mature complicated cataract (Fig 7). Seven months

later a penetrating keratoplasty, anterior segment reconstruction (during surgery a wall-to wall anterior synechia was found), cataract extraction and posterior chamber intraocular lens implantation were performed under general anesthesia. The postoperative course was without any complication and her pinhole visual acuity improved to 0.4 (Fig.8).

Discussion

Even though rare, the number of cases of fungal keratitis and endophthalmitis has been increasing during recent decades. However, diagnosis is often difficult, especially in temperate zones, owing to less awareness of and experience with the management of these mycoses [5]. Moreover fungal infection can be associated with invasion of epithelia by previous bacterial infection. Diagnosis of mycotic keratitis is based on clinical presentation, non-invasive in vivo methods together with in vitro conventional microbiological investigations and molecular methods. Non-invasive techniques include confocal microscopy, and anterior segment optical coherence tomography that allow in vivo examination of the cornea [2].

Coagulase-negative staphylococci (CoNS) are part of the indigenous microbiota of the conjunctival sac and the eye lid. These Gram-positive bacteria represent a relatively large group of species with variable antibiotic susceptibility. In this case, only the isolate from anterior chamber fluid was identified as *Staph. hominis* and can be considered a possible causative agent of keratitis.

CoNS were isolated from less clinically relevant specimens (corneal swabs) and probably represent contamination. Failure of therapy was most likely caused by the development of resistance to tobramycin, moxifloxacin, ciprofloxacin, oxacillin and cotrimoxazole as shown in the CoNS strain isolated six weeks later. Unfortunately this strain was not identified at the species level but both the *Staph. hominis* strain and CoNS isolated at the time of institution of therapy were susceptible to the antibiotic drugs tested, including those mentioned above.

Isolation of *Bacillus* sp. from a swab of the corneal defect was considered contamination owing to its low pathogenic potential, ubiquitous nature of *Bacillus* spores and low clinical relevance of swab technique. *Bacillus* species belongs to rare eye pathogens nevertheless we cannot exclude mixed infection caused by *Fusarium* and *Bacillus* [6]. *Fusarium* keratitis with progression to endophthalmitis developed probably as a contamination of the not completely healed corneal graft during the convalescence period at home. Intensive topical antibiotic-corticosteroid eye drop treatment is an important risk factor for opportunistic fungal infection of the eye. Topical corticosteroids encourage fungal growth and epithelial invasion by compromising host defense mechanisms. In our case, the patient was on intensive topical antibiotic-corticosteroid therapy after the first penetrating keratoplasty.

Fusarium species, a filamentous fungus found commonly in air and water, have been described as the most common cause of fungal keratitis, particularly in tropical countries [7]. Most infections have been reported in farmers, and the infections are often preceded by trauma. Other risk factors include the use of antibiotics and corticosteroids, pre-existing eye diseases, surgery, and the use of contact lenses [8]. There were multiple risk factors in our patient: work in agriculture, possible ocular trauma, and use of antibiotics and corticosteroids. Also her dry eyes and rheumatoid arthritis predisposed her to ocular surface infection.

Fusarium corneal infections represent a difficult-to-treat keratitis with serious consequences, because of the severity of the disease and its refractoriness to antifungal medications [9]. It can cause serious complications, such as descemetocoele, perforation, endophthalmitis, and blindness [10].

Current treatment protocols for mycotic infections are far from optimal due to late diagnosis, resistance to antifungal therapy and the limited number of suitable antifungal drug formulations with satisfactory penetration into eye tissues [11]. Today, second-generation triazole antimycotics, in particular voriconazole, appear to be standard treatment of ocular

infections caused by molds [5, 8, 11-18]. The triazoles inhibit the biosynthesis of ergosterol, an essential component of the fungal cell membrane. Voriconazole has been shown to have a broad spectrum of activity against potentially pathogenic fungi which are involved in eye infections, such as *Aspergillus* species, *Candida* species, *Paecilomyces lilacinus*, *Cryptococcus neoformans*, *Scedosporium* species and others [19-22]. It has excellent *in vitro* activity with fungicidal effect against *Aspergillus* species, some of which may be resistant to amphotericin B and itraconazole [23-24]. However, activity against *Fusarium* species has been variable: a series of three patients with resistant *Fusarium* ocular infection has been described [25].

Corneal collagen cross-linking (CXL) with application of riboflavin and ultraviolet A (UVA) was introduced in 2003 [26] to halt the progression of keratoconus, pellucid marginal degeneration, and corneal ectasia [27-29]. It consists of polymerization of stromal fibers with the combined action of riboflavin (a photosensitizing substance) and UVA rays. Recently, CXL was proposed for the treatment of various corneal infections and melting on the basis of *in vitro* results [30-31]. The effect of UV rays against microorganisms has been demonstrated in many articles [32-33]. Studies have also shown that riboflavin acts as a photomediator to inactivate pathogens in plasma, platelets and red blood cells [34-35]. Additionally, it has been shown that CXL increases the resistance of the cornea against enzymatic digestion by microorganisms [36]. However, a case of severe corneal thinning and melting in a patient who had a CXL procedure as a treatment for herpetic keratitis was also published [36]. In our case, CXL was performed without any complications as a part of intensive anti-inflammatory treatment.

In conclusion, corneal trauma and topical antibiotic-corticosteroid therapy are important risk factors in the pathogenesis of keratomycosis. In our case voriconazole, antibacterial

antibiotics and CXL were effective in the management of a severe polymicrobial corneal ulcer and endophthalmitis.

Acknowledgments

The paper was supported by Charles University in Prague - Programme P37/07 (PRVOUK) and SVV266902.

References:

1. Centers for Disease Control (CDC) (2006) Update: *Fusarium* keratitis – United States, 2005 - 2006. *Morb Mortal Wkly Rep* 55: 563-564.
2. Thomas PA, Kaliyamurthy J (2013) Mycotic keratitis: epidemiology, diagnosis and management. *Clin Microbiol Infect* 19:210-220
3. Vajpayee RB, Gupta SK, Bareja U, Kishore K (1990) Ocular atopy and mycotic keratitis. *Ann Ophthalmol* 22: 369-372.
4. Dursun D, Fernandez V, Miller D, Alfonso EC (2003) Advanced *Fusarium* keratitis progressing to endophthalmitis. *Cornea* 22: 300-303.
5. Polizzi A, Siniscalchi C, Mastromarino A, Saccá SC (2004) Effect of voriconazole on a corneal abscess caused by *Fusarium*. *Acta Ophthalmol. Scand.* 82: 762-764.
6. Choudhuri KK, Sharma S, Garg P, Rao GN (2000) Clinical and microbiological profile of *Bacillus* keratitis. *Cornea* 19: 301-306.
7. Marangon FB, Miller D, Giaconi JA, Alfonso EC (2004) In vitro investigation of voriconazole susceptibility for keratitis and endophthalmitis fungal pathogens. *Am J Ophthalmol* 137: 820-825.
8. Klont RK, Eggink CA, Rijs AJMM, Wesseling P, Verweij PE (2005) Successful Treatment of *Fusarium* Keratitis with Cornea Transplantation and Topical and Systemic Voriconazole. *Clinical Infectious Diseases* 40: e110-112.
9. Reuben A, Anaissie E, Nelson PE, et al. (1989) Antifungal susceptibility of 44 clinical isolates of *Fusarium* species determined by using a broth microdilution method. *Antimicrob Agents Chemother* 33: 1647-1649.
10. Dóczy I, Gyetvai T, Kredics L, et al. (2004) Involvement of *Fusarium* spp. in fungal keratitis. *Clin Microbiol Infect* 10: 773-776.
11. Hariprasad SM, Mieler WF, Lin TK, Sponsel WE, Graybill JR (2008) Voriconazole in the treatment of fungal eye infections: a review of current literature. *Br J Ophthalmol* 92: 871-878.
12. Nulens E, Eggink C, Rijs AJMM, Wesseling P, Verweij PE (2003) Keratitis Caused by *Scedosporium apiospermum* Successfully Treated with a Cornea Transplant and Voriconazole. *J Clin Microbiol* 41: 2261-2264.
13. Prats CH, Tello FL, San José AB, Otaolaurruchi JS, Baines JPO (2004) Voriconazole in Fungal Keratitis Caused by *Scedosporium apiospermum*. *Ann Pharmacother* 38: 414-417.
14. Breit SM, Hariprasad SM, Mieler WF, Shah GK, Mills MD, Grand MG (2005) Management of endogenous fungal endophthalmitis with voriconazole and caspofungin. *Am J Ophthalmol* 139: 135-140.
15. Huynh TK, Franzco LRL, Ellis D (2007) Late-onset post-traumatic *Phaeoacremonium parasiticum* endophthalmitis. *Clinical and Experimental Ophthalmology* 35: 366-368.
16. Sponsel W, Chen N, Dang D, Paris G, Graybill J, Najvar LK, Zhou L, Lam KW, Glickman R, Scribbick F (2006) Topical Voriconazole as a Novel Treatment for Fungal Keratitis. *Antimicrobial Agents and Chemotherapy* 50: 262-268.
17. Jhanji V, Sharma N, Mannan R, Titiyal JS, Vajpayee RB (2007) Management of tunnel fungal infection with voriconazole. *J Cataract Refract Surg* 33: 915-917.

18. Kernt M, Neubauer AS, De Kaspar HM, Kampik A (2009) Intravitreal voriconazole: in vitro safety-profile for fungal endophthalmitis. *Retina* 29: 362-370.
19. Espinel-Ingroff A, Boyle K, Sheehan DJ (2001) In vitro antifungal activities of voriconazole and reference agents as determined by NCCLS methods: review of the literature. *Mycopathologia* 150: 101-115.
20. Ghannoum MA, Kuhn DM (2002) Voriconazole: Better chances for patients with invasive mycoses. *Eur J Med Res* 7: 242-256.
21. Marco F, Pfaller MA, Messer SA, et al. (1998) Antifungal activity of a new triazole, voriconazole (UK-109,496), compared with three other antifungal agents tested against clinical isolates of filamentous fungi. *Med Mycol* 36: 433-436.
22. Sabo JA, Abdel-Rahman SM (2000) Voriconazole: A new triazole antifungal. *Ann Pharmacother* 34: 1032-1043.
23. Maesaki S, Iwakawa J, Higashiyama Y, et al. (2000) Antifungal activity of a new triazole, voriconazole (UK-109496), against clinical isolates of *Aspergillus*. *J Infect Chemother* 6: 101-103.
24. Sutton DA, Sanche SE, Revankar SG, et al. (1999) In vitro amphotericin B resistance in clinical isolates of *Aspergillus terreus*, with a head-to-head comparison to voriconazole. *J Clin Microbiol* 37: 2343-2345.
25. TU EY, McCartney DL, Beatty RF, Springer KL, Levy J, Deepak E (2007) Successful Treatment of Resistant Ocular Fusariosis With Posaconazole (SCH-56592). *Am J Ophthalmol* 143: 222-227.
26. Wollensak G, Spoerl E, Seiler T (2003) Riboflavin/ultraviolet-A-induced collagen crosslinking for the treatment of keratoconus. *Am J Ophthalmol* 135: 620-627.
27. Kanellopoulos AJ, Binder PS (2007) Collagen cross-linking (CCL) with sequential topography-guided PRK: a temporizing alternative for keratoconus to penetrating keratoplasty 26: 891-895.
28. Hafezi F, Kanellopoulos J, Wiltfang R, Seiler T (2007) Corneal collagen crosslinking with riboflavin and ultraviolet A to treat induced keratectasia after laser in situ keratomileusis. *J Cataract Refract Surg* 33: 2035-2040.
29. Raiskup-Wolf F, Hoyer A, Spoerl E, Pillunat LE (2008) Collagen crosslinking with riboflavin and ultraviolet-A light in keratoconus: long-term results. *J Cataract Refract Surg* 34: 796-801.
30. Iseli HP, Thiel MA, Hafezi F, Kampmeier J, Seiler T (2008) Ultraviolet A/riboflavin corneal cross-linking for infectious keratitis associated with corneal melts. *Cornea* 27: 590-594.
31. Gao XW, Zhao XD, Li WJ, Zhou X, Liu Y (2012) Experimental study on the treatment of rabbit corneal melting after alkali burn with collagen cross-linking. *Int J Ophthalmol* 5: 147-150.
32. Rau H (1960) A transportable apparatus for UV irradiation in final disinfection of patient rooms [in German]. *Dtsch Gesundheitsw* 15: 148-151.
33. Müller G, Goethe H, Hermann R (1972) Ship drinking water disinfection using UV irradiation. II [in German]. *Zentralbl Bakteriolog Orig B* 156: 361-372.

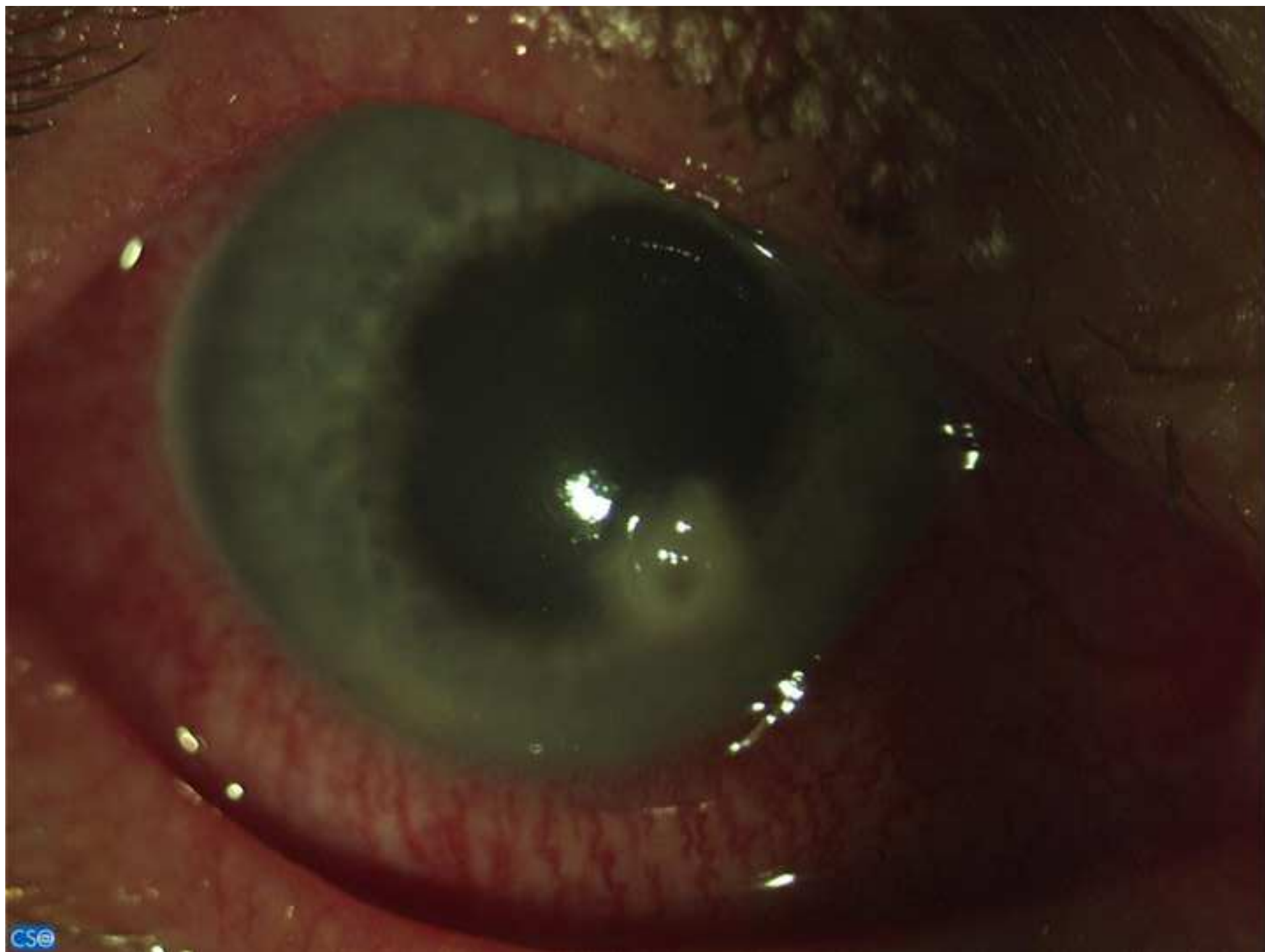
34. Asano H, Lee CY, Fox-Talbot K, et al. (2007) Treatment with riboflavin and ultraviolet light prevents alloimmunization to platelet transfusions and cardiac transplants. *Transplantation* 84: 1174-1182.
35. Goodrich RP (2000) The use of riboflavin for the inactivation of pathogens in blood products. *Vox Sang* 78(suppl 2): 211-215.
36. Ferrari G, Iuliano L, Viganó M, Rama P (2013) Impending corneal perforation after collagen cross-linking for herpetic keratitis. *J Cataract Refract Surg* 39: 638-641.

Figures

1. Right eye at presentation
2. Progression of ulcer and corneal thinning
3. Right eye 2 days after the first penetrating keratoplasty
4. A small purulent abscess was present under corneal epithelium in the substantia propria (or stroma of cornea) (H&E stain, original magnification x10)
5. Severe ulcerative keratitis and endophthalmitis 4 months after the first hospitalization
6. Resolution of the infection and inflammation
7. Dense vascular leucoma, wall-to-wall anterior synechias and mature cataract
8. Right eye 1 month after penetrating re-keratoplasty, anterior segment reconstruction surgery and IOL implantation

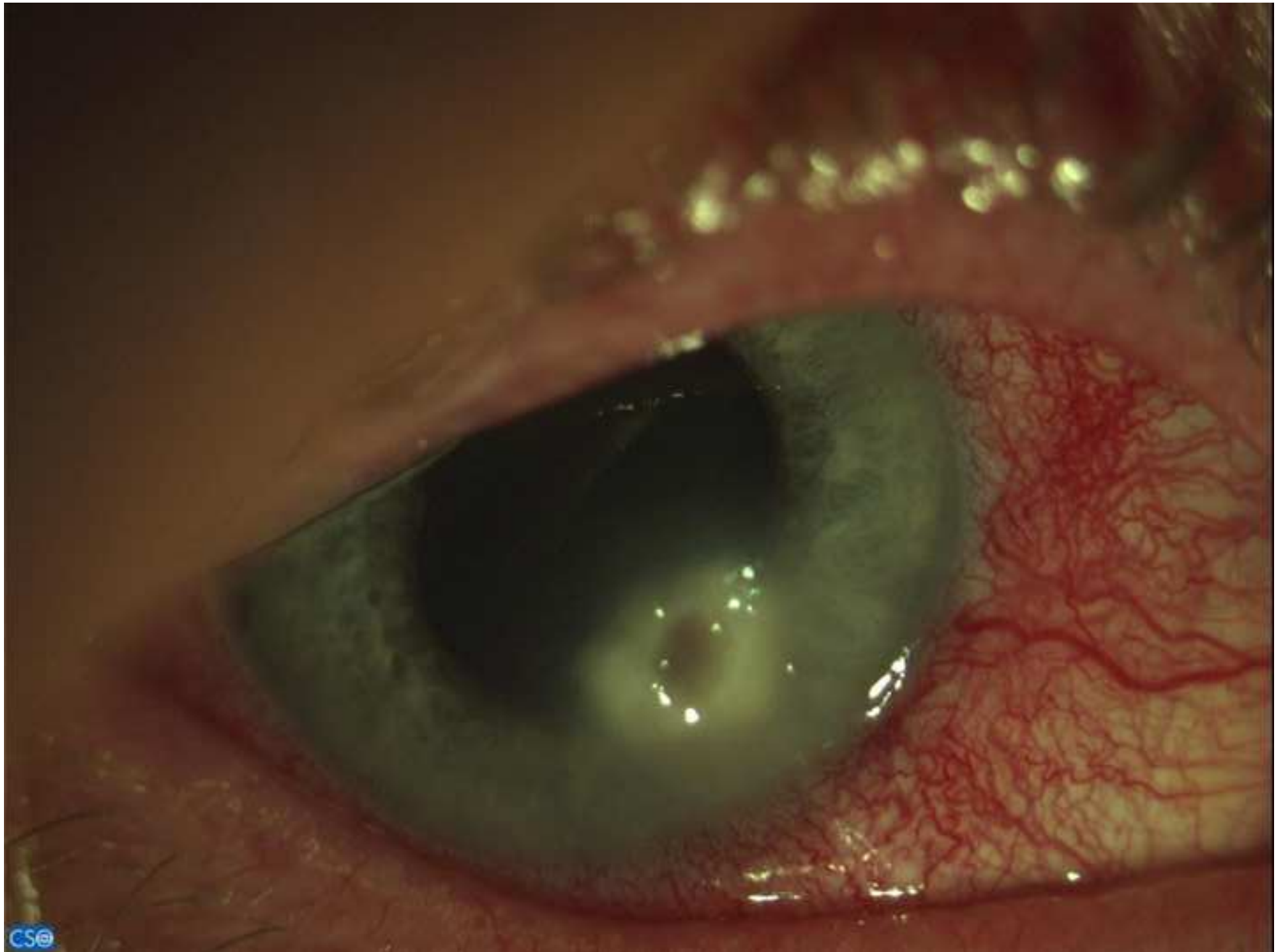
Figure

[Click here to download high resolution image](#)



Figure

[Click here to download high resolution image](#)



Figure

[Click here to download high resolution image](#)

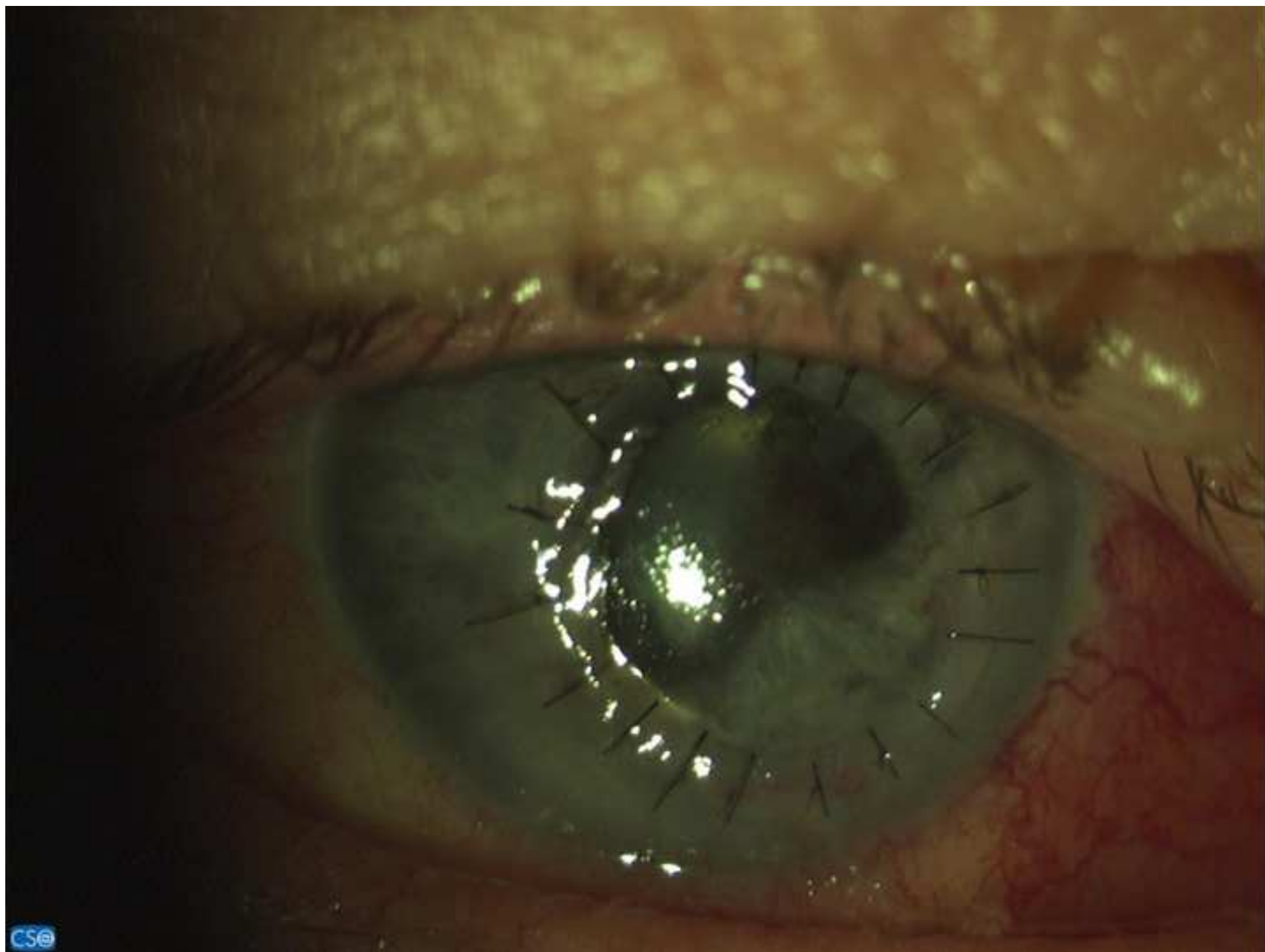
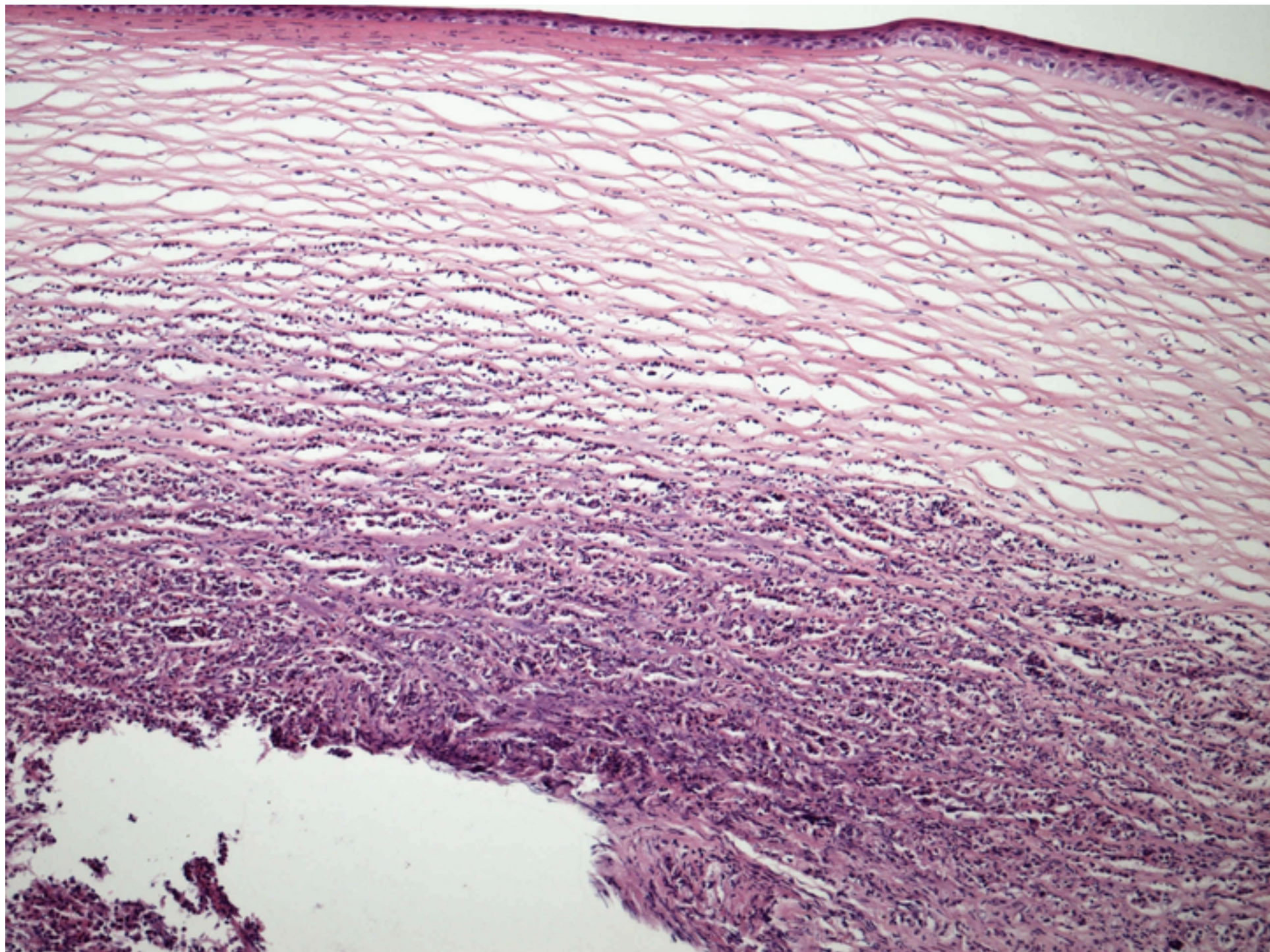
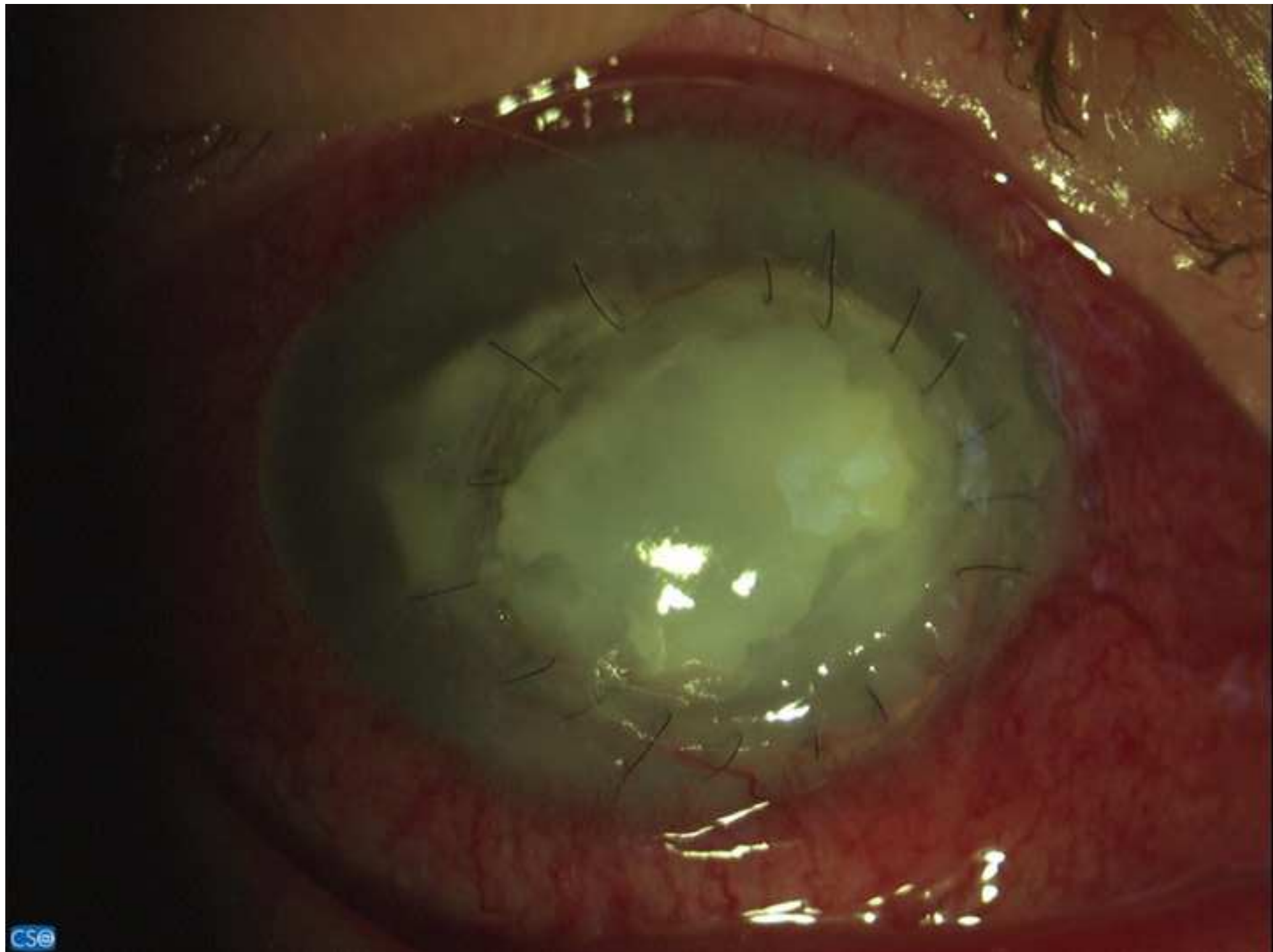


Figure
[Click here to download high resolution image](#)



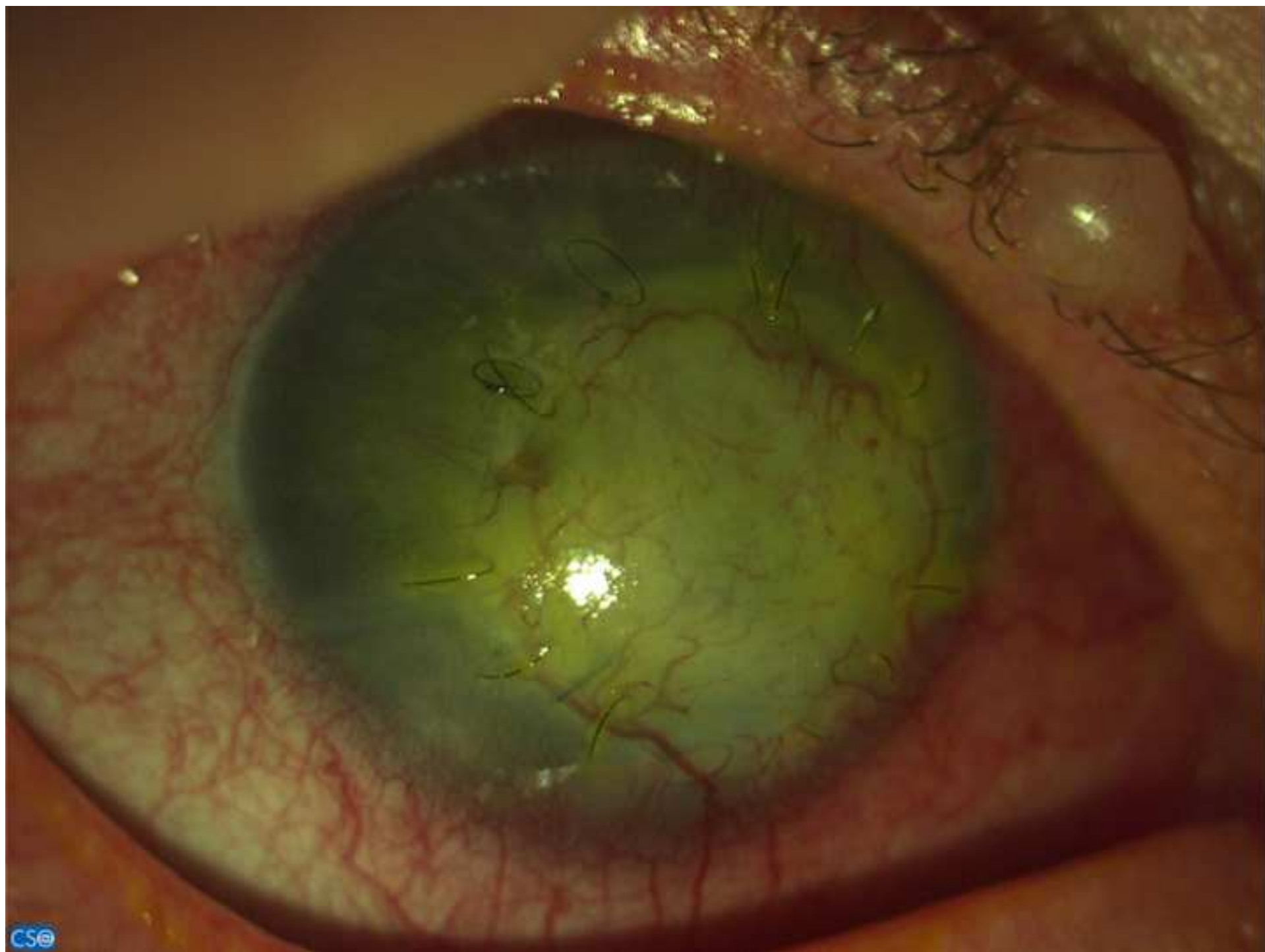Figure

[Click here to download high resolution image](#)



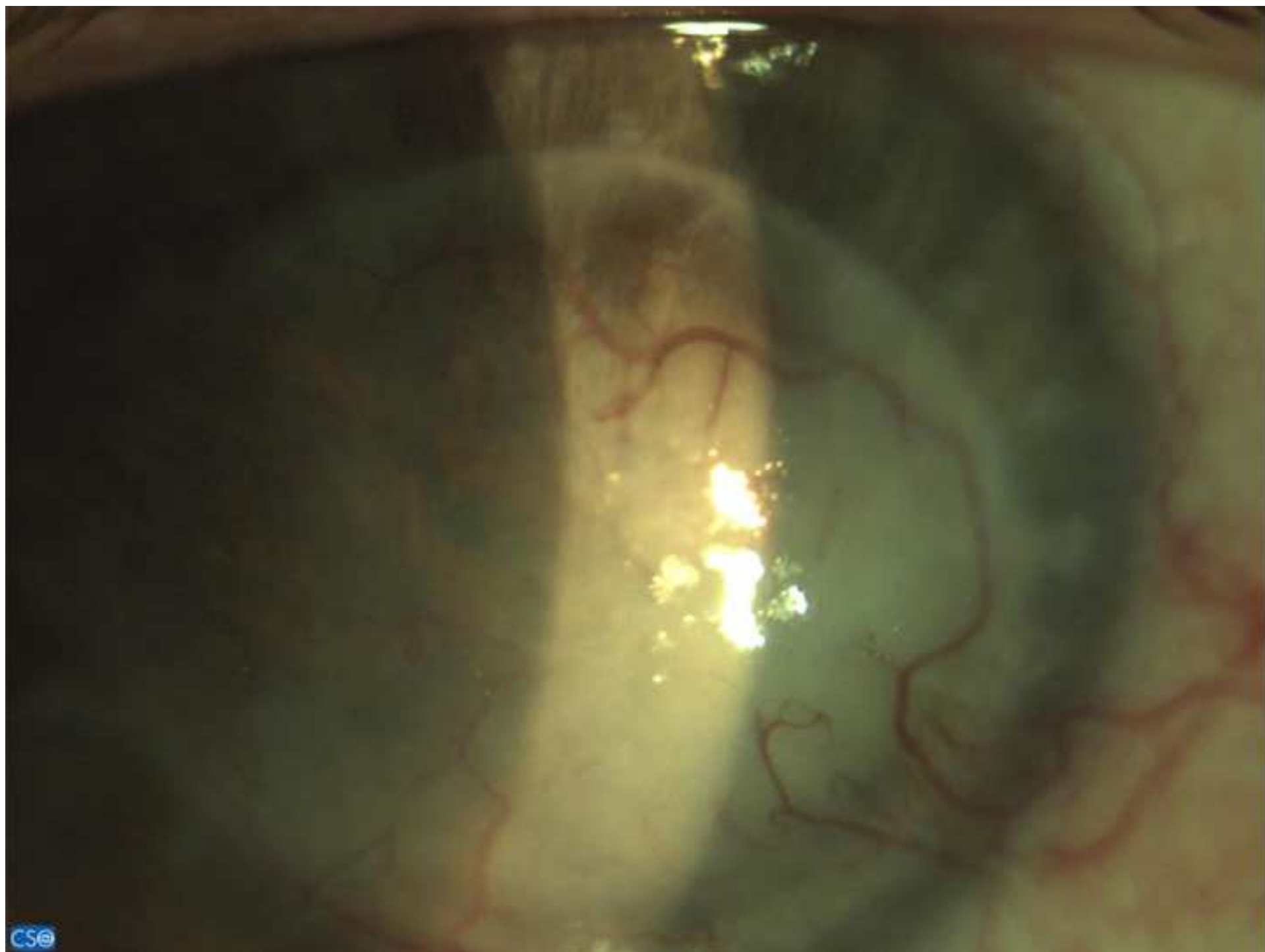Figure

[Click here to download high resolution image](#)



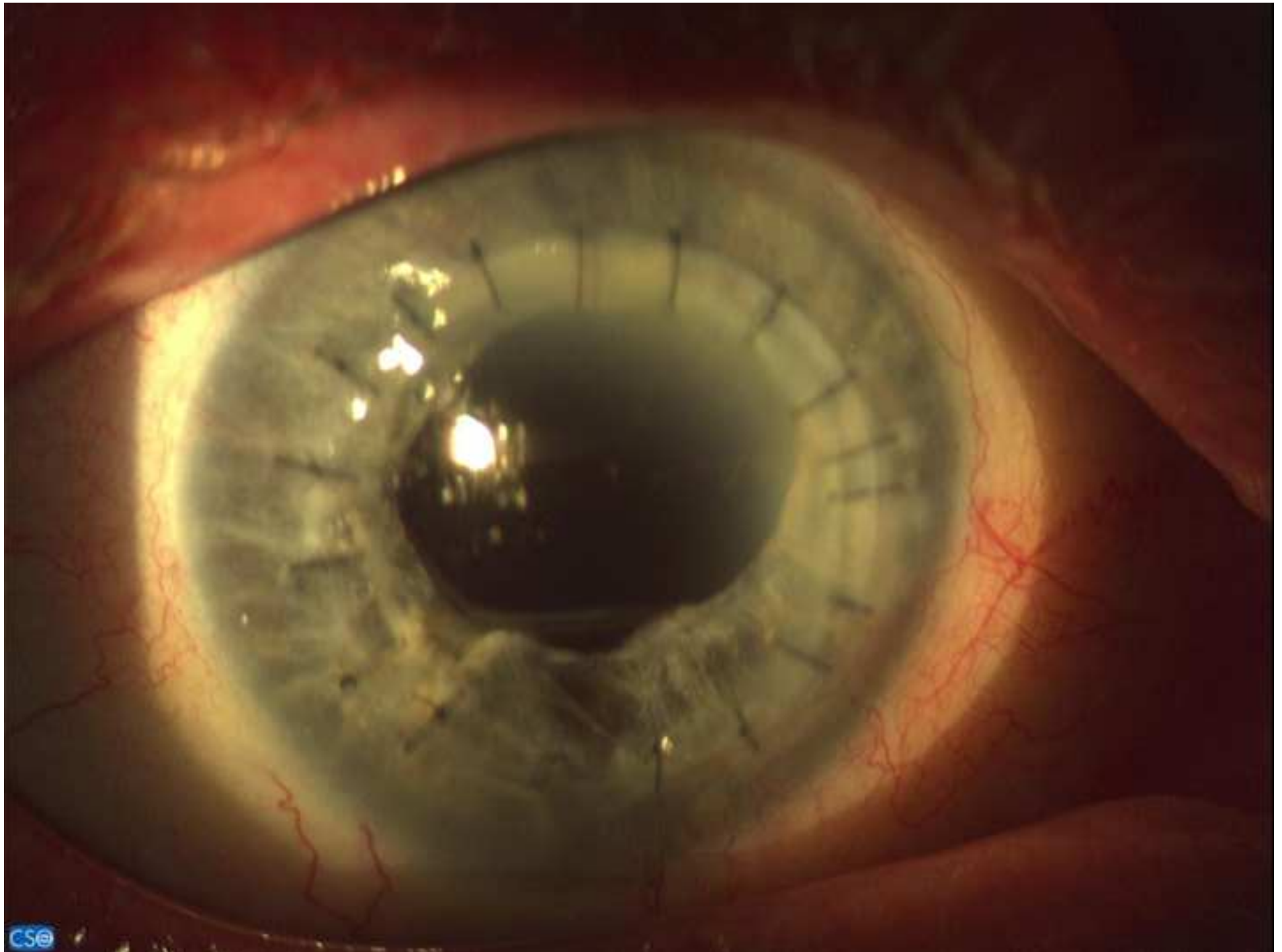
Figure

[Click here to download high resolution image](#)



Figure

[Click here to download high resolution image](#)



All the points have been revised according to your suggestions.